

# Present status of refractive surgery

BENJAMIN F. BOYD, M.D., F. A. C. S.\*

## Why so Many Years Before Final Acceptance

Refractive surgery has stimulated great interest and created significant impact in modern ophthalmology? These techniques are fundamentally based on the scientific and surgical principles established by JOSE BARRAQUER, M. D. (Bogota, Colombia) during the past 36 years. Why has it taken so long for ophthalmologists to accept these new concepts and methods?

The answer to this question possibly lies on the fact that there are other remedies to ocular refractive errors, such as eye glasses and contact lenses. This has made it more difficult to accept the fact that the only way to reduce the refractive errors of the eye in a permanent way is to modify the shape of the cornea.

Jose Barraquer emphasizes that historically, a good many years have elapsed between the discovery and the acceptance of a new fundamental therapeutic method. It took Gonin 15 years to persuade his colleagues that a retinal tear had to be closed in order to cure a retinal detachment, even though at the time there were no other effective alternatives. Almost a generation has passed from the time Ridley

performed his first operations at the end of the 40's until their new impulse in the 70's, to become widespread and established in our times. Of course, the difficulty to convince ophthalmologists that the shape of the cornea can be modified to **reduce** (mind you, not correct) refractive errors by performing surgery in a healthy organ, such as the cornea, has been even more difficult and has taken even longer.

Although refractive corneal surgery has taken many years to be accepted,<sup>1</sup> probably it is here to stay. Of course, its evolution will continue and improvements will be added to make it still safer and more accurate. Also, as with all surgical procedures, current techniques will have to evolve and be simplified.

In this special issue dedicated to Refractive Surgery, I can only present to you the **highlights** of the subject. The first Atlas and Textbook on this new sub-specialty has just been published. You may consult it for the step by step surgical methods and techniques and more profound knowledge of the subject. Its title: "Refractive Surgery with the Masters" Volume II, 30th Anniversary Edition, HIGHLIGHTS OF OPHTHALMOLOGY Book Series.

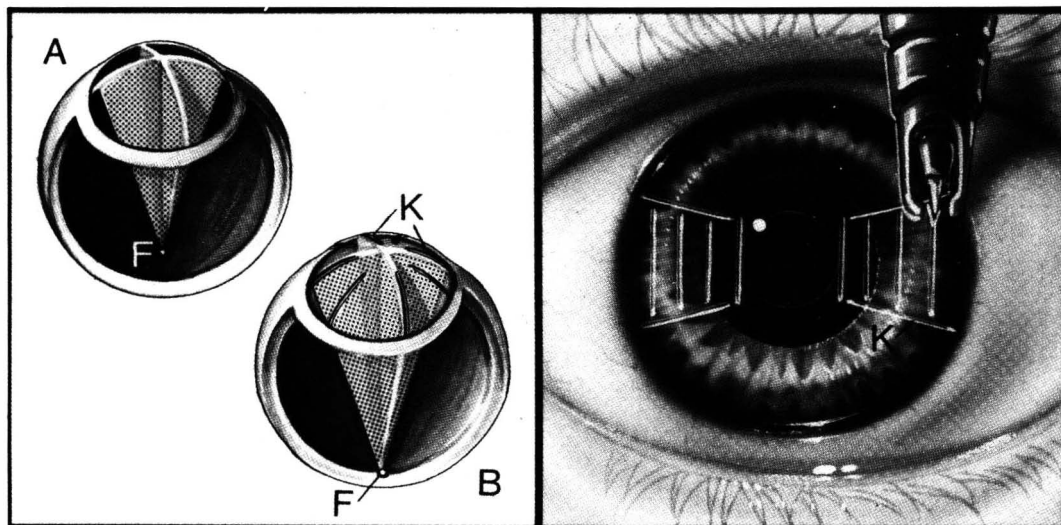


Fig. 1 — Classification of refractive surgery techniques. Category I — Relaxation of corneal fibers. R. K. for low and moderate myopia — Astigmatic keratotomies  
(LEFT) (A) Shows a pre-op conceptual view of myopia. Light rays passing through both meridians (dot shaded areas) have focal point (F) within the vitreous cavity, anterior to the retina. (B) After placement of the radial keratotomy incisions (K), the light rays passing through both meridians are now focused (F) on the retina due to the flattened central corneal curvature. (RIGHT) Astigmatic keratotomy incisions (K) relax the corneal curvature when placed in the meridian of high corneal curvature in order to reduce astigmatism.

\* Editor HIGHLIGHTS OF OPHTHALMOLOGY  
President Pan American Association of Ophthalmology

## Classification of Refractive Surgical Techniques (F-8)

The current methods involve three different types of procedures. They change the refraction of the eye through the following surgical principles:

1) By **relaxation of the corneal fibers**. Within this group we find **radial keratotomy** (fig. 1 — Left\*) for the reduction of low or moderate myopia and the operations to reduce astigmatism, such as the Ruiz astigmatic keratotomies (Fig. 1 — Right\*) and Troutman's "relaxing incision".

2) By **subtraction of tissue**, which involves a modification of the corneal thickness. The classical example of this group of surgical procedures is **keratomileusis**. In this operation, tissue is subtracted from the optical center of the cornea for the correction of myopia (Fig. 2 — Left\*) and from its periphery for the correction of hyperopia (Fig. 2 — Right\*). Troutman's wedge resection for the reduction of astigmatism also falls within this category.

3) By **addition of tissue**, which also involves a modification of the corneal thickness. Barraquer's

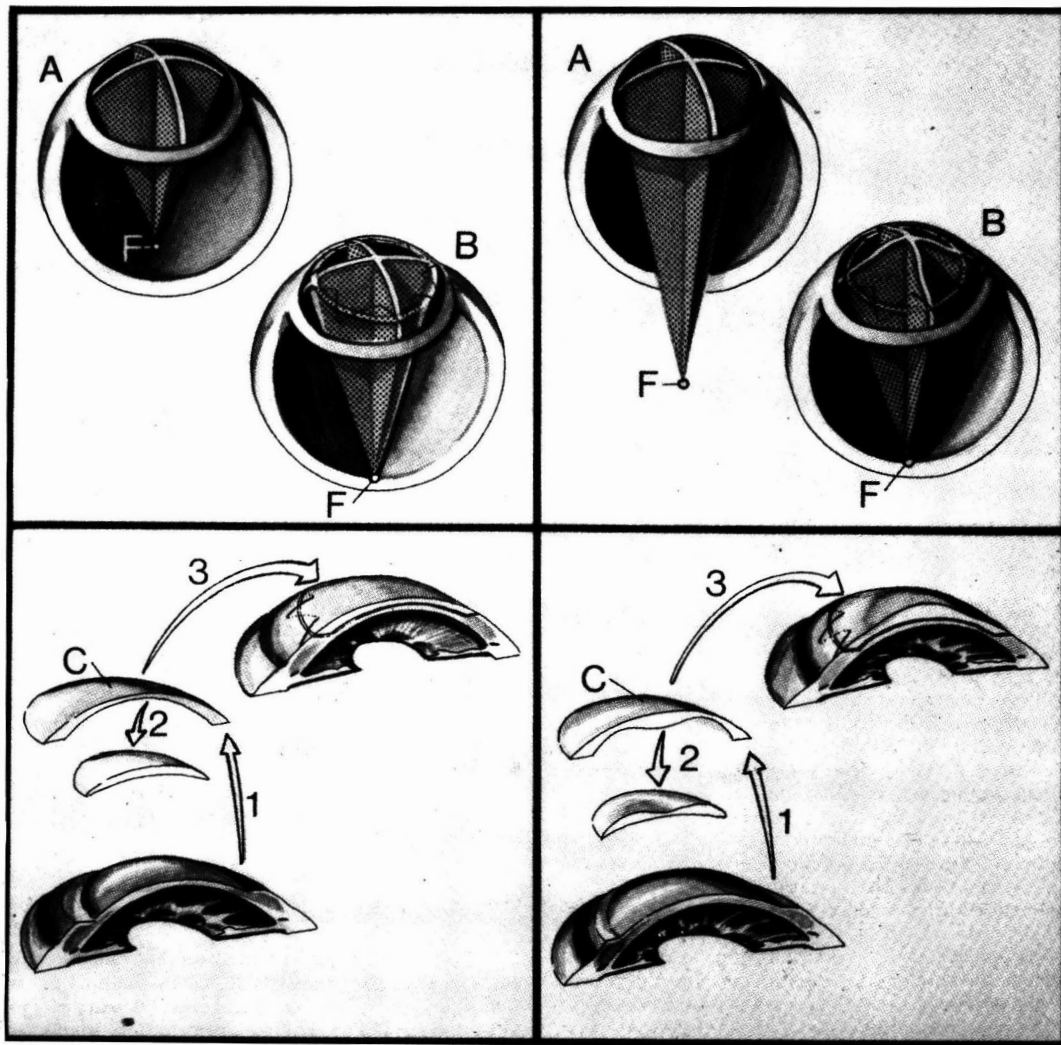


Fig. 2 — Classification of refractive surgery techniques. Category II — Subtraction of tissue. Keratomileusis for high myopia and high hyperopia. (TOP LEFT) Pre-op refraction view (A) shows a case of myopia as revealed by the light rays (dot shaded areas) which focus at point (F) anterior to the retina. (BELOW LEFT) A layer of tissue is removed from the patient's cornea (1) with the microkeratome. A minus-shaped lenticule (C) is produced by subtracting tissue (arrow-2) from the optical center of the microkeratomized section. The reshaped corneal tissue (C) is placed (3) on the recipient's (patient) corneal bed. Result: (TOP LEFT-B) flattened central corneal curvature and reduced dioptric power. Light rays now focus on the retina (F). (TOP RIGHT) Pre-op refraction view (A) shows a case of hypermetropia where light rays (dot shaded areas) are focused (F) beyond the retina. (BELOW RIGHT) A layer of tissue is removed from the patient's cornea (1) with the microkeratome. A plus-shaped lenticule of corneal tissue (C) is produced by subtracting tissue (arrow-2) from the periphery of the microkeratomized section. The reshaped corneal tissue (C) is placed (3) on the patient's corneal bed. Result: (TOP RIGHT-B) Steepened central corneal curvature and increased dioptric power. Light rays now focus on the retina (F).

keratophakia to correct hypermetropia and aphakia and Kaufman's epikeratophakia (fig. 3\*) to correct high myopia and high hyperopia fit into this category. In both, tissue is added to the optical center of the cornea to correct hyperopia, or to its periphery, to

make it flatter and thus correct myopia. In this group we could also include Choyce's intracorneal inclusion of plastic lenticules, which may be used to correct myopia or hyperopia, although their long-term results are still unknown.

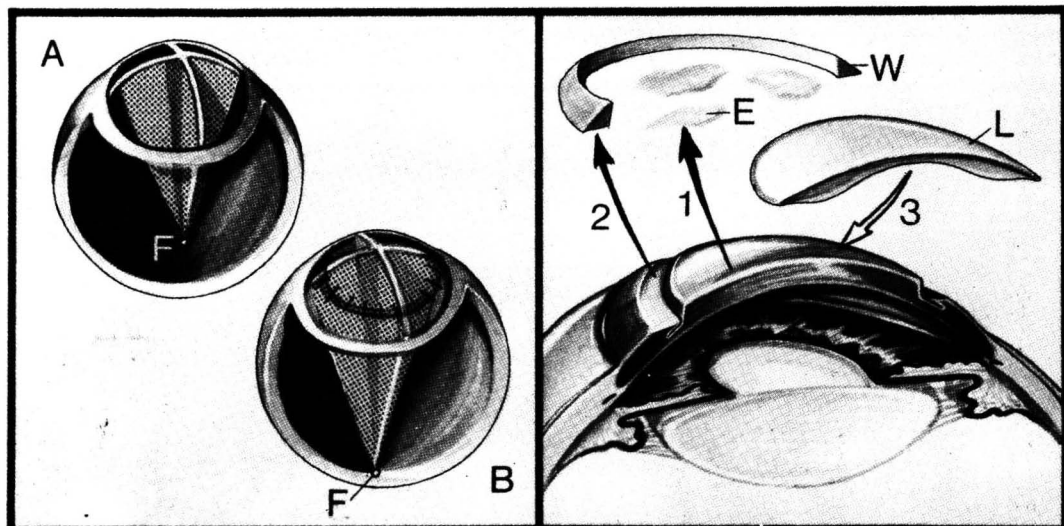


Fig. 3 — Classification of refractive surgery techniques. Category III — Addition of tissue. Epikeratophakia for high myopia. (LEFT) The pre-op myopic condition (A) shows light rays (dot shaded areas) focused anterior to the retina (F). (RIGHT) Epikeratophakia involves removal (1) of patient's epithelium (E) and sometimes a circular wedge (W) of tissue (2). A minus lens shaped corneal lenticule (L) is sutured to the prepared area of the patient's cornea (3). The post-op refractive result is seen at (LEFT-B). Light rays (dot shaded areas) now focus on the retina (F).

The advantages of the relaxing techniques (fig. 1) over the subtraction of tissue procedures (fig. 2) are that they are easier to perform, the instrumentation required is less sophisticated and technically could be performed by most ophthalmologists. The techniques that modify the thickness of the cornea (groups 2 and 3) are being accepted more gradually because for their higher complexity, their slower postoperative visual rehabilitation and the higher cost of the equipment necessary to perform them.

At present, pre-cut lenticules are being provided for the third group of operations by Allergan Medical Optics, mainly for epikeratophakia.

Indications for Refractive Surgery Procedures (F-8)

Jose Barraquer's main indications are: 1) intolerance to the conventional methods for the correction of the ametropia (eye glasses and contact lenses). 2) The need for better vision without the use of glasses or contact lenses. There are many people whose profession demands a vision of 20/40 without any visual aids. In many cases (not all), the surgery can fulfill this need. Those patients who wish to have better vision than that provided by the surgery are able to wear spectacles that are both thinner and more aesthetic than the ones they needed pre-operatively. In any case, they will not be as dependant

on the glasses as they were before. 3) Patients who, after undergoing penetrating keratoplasty with subsequent good tolerance of contact lenses, begin to develop progressively larger astigmatism because of ectasia of the edges of the graft or of the peripheral cornea. These patients become intolerant to contact lenses because of constant instability of the lenses in the cornea. They are good candidates for refractive surgery because, by reducing the astigmatism, they will be able to wear contact lenses as previously.

Operation of Choice for Different Refractive Conditions (F-8)

Low and Intermediate Myopia (F-5)

There is a general consensus that **radial keratotomy** is the operation of choice in patients up to 5 diopters of myopia and older than 20 years of age, although some experts may perform R. K. in myopia up to 8 diopters. RICHARD VILLASENOR, M. D., from the University of Southern California at Los Angeles and one of the most prestigious refractive surgeons in the United States, performs radial keratotomy in: 1) Patients with myopia between -2.00 and -8.00 diopters who have realistic expectations as to their outcome. Six to eight diopter myopes who are able to correct 3 or 4 diopters are some of the happiest pa-

tients if they understand prior to this surgery that only partial correction is obtainable. 2) Eyes that are free of external disease; 3) A visual **potential** that is at least 20/30 or better; and 4) Absence of macular disease.

**Predictability of Radial Keratotomy:** CASIMIR A. SWINGER, M. D., from the Manhattan Eye, Ear and Throat Hospital, the New York Eye and Ear Infirmary and Mount Sinai School of Medicine in New York City, strongly recommends that every surgeon should analyze his/her results critically, which will depend on his/her technique, the knife-blade that one uses, the force that one exerts on the cornea, the depth of the incisions, all in conjunction with known factors such as the patient's age, the amount of myopia present, the optic zone size, the number of incisions, etc. This critical analysis is more significant if integrated with some computer program to determine exactly what **personal results** you are getting instead of relying on the statistics available in the literature, because you may be getting entirely different effects. Of course, one must start with something, and most courses provide nomograms or tables which can be used as a starting point. (Editor's Note: I refer you to Dr. Villaseñor's Nomogram in the new Atlas and Textbook, "Refractive Surgery with the Masters," Chapter 2; see also Chapter 3 with Marguerite McDonald, Chapter 4 with George Waring, dedicated to Radial Keratotomy. This is Volume II, 30th Anniversary Edition, HIGHLIGHTS OF OPHTHALMOLOGY Book Series.) Based on your own technique then try to apply the data to future patients. Ultimately, one should derive a personalized nomogram to use in determining the surgical variables.

**Complications of Radial Keratotomy:** The frequency of complications where vision might be compromised such as perforation into the eye with infection and cataract formation, ulcers of the cornea, etc. is very low.

Dr. Villaseñor has observed that many patients have **some glare**, although most patients **rapidly overcome it**. **Fluctuating vision** seems to be a factor related to the pre-operative degree of myopia. Those with high degrees of myopia have greater fluctuation of vision and for a longer period of time. Certainly the groups where only four incisions have been made on the cornea become stable faster and have significantly less fluctuation of vision. This does not seem to be a serious problem.

(Editor's Note: For the step by step surgical procedure and surgical principles of radial keratotomy, I refer you to the new Atlas and Textbook "Refractive Surgery with the Masters," Chapters 2, 3, and 4, Vol. II, 30th Anniversary Edition of the HIGHLIGHTS).

#### High Myopia (F-5)

For patients whose myopia is beyond that able to be corrected by radial keratotomy (i. e. usually -6D, definitely all those over -8D), the operations of choice are either **myopic keratomileusis** (Fig. 2) or **myopic epikeratophakia** (Fig. 3). These are more

difficult and complex procedures that may be associated with greater morbidity which may result from freeze damage to the tissues (keratomileusis) or the use of lyophilized tissue (epikeratophakia). Epikeratophakia is technically less complicated than keratomileusis.

**Myopic Keratomileusis:** it is **primarily** performed today as **autoplasmic** surgery where the patient's own cornea is reshaped to create the minus (-) lenticule. Because it is necessary to leave a certain thickness behind in the posterior bed, it is only possible to correct a maximum of about 15 diopters of myopia.

The **autoplasmic myopic keratomileusis** for myopia between 6 and 15 diopters gives excellent results in the hands of a surgeon who is familiar with the technique. It has a rapid visual recovery, faster than epikeratophakia, no donor tissue is required, and it is an excellent operation but difficult to perform.

Homoplasmic myopic keratomileusis is a fairly recent development which is indicated in patients with 20 or 25 diopters of myopia.

In the **homoplasmic myopic keratomileusis**, a keratotomy is performed on the patient's eye and a pre-carved lens delivered to the surgeon by a laboratory or prepared in advance by the surgeon from a donor eye is placed over the visual axis. This operation has a number of advantages over the autoplasmic method. **First**, it eliminates all of the lathing and computer calculations necessary in the autoplasmic. The surgeon merely needs to know how to operate the microkeratome. **Two**, because the donor tissue used for the production of the lenticule is obtained from a full-thickness cornea, this allows the surgeon to achieve almost unlimited corrections just as with myopic epikeratophakia. Its disadvantage is that it requires donor tissue and visual recovery is slower than in the autoplasmic method.

**Myopic Epikeratophakia:** This operation alters the anterior curvature of the cornea by the addition of a machine-carved, **preserved** donor lenticule obtained through **Allergan Medical Optics**. Its purpose is to correct high ametropias, either high myopias (fig. 3) or high hyperopias (aphakia). In myopia it is indicated to correct high myopia (from -6D and up), essentially to treat **adult** patients with stable myopia who are contact lens and spectacle intolerant and that are too highly myopic for radial keratotomy. As described by MARGUERITE McDONALD, M. D., one of the pioneers and most experienced surgeons in this field, the "donor lenticule" tissue is reshaped to correct the refractive error of each specific patient, based on the patient's manifest refraction and K-reading. This lenticule has no living keratocytes, no living epithelial cells, it has only Bowman's membrane and the collagen of the stroma and has been cut away from Descemet's side. In cases of myopia, it is much thinner in the middle than it is at the periphery where it has a large shoulder, shaped very much like a high minus contact lens.

The tissue is sown onto the anterior surface of the cornea after the central epithelium has been removed and a small annular keratotomy is made. The keratocytes repopulate the collagen. Eventually

the patient has someone else's Bowman's membrane and collagen on top of his/her cornea, but his own epithelium and his own keratocytes.

Dr. McDonald considers that epikeratophakia has the following advantages: (1) it is a safe operation because it is extraocular and for the most part extra-corneal; (2) it does not involve splitting the stroma or the visual axis; (3) it is easily reversible; (4) it does not require expensive instrumentation; (5) most ophthalmic surgeons who do cataract surgery can perform this procedure. (For the step by step surgical technique and surgical principles, beautifully illustrated, see the new Atlas and Textbook "Refractive Surgery with the Masters," Vol. II, 30 th Anniversary Edition of the HIGHLIGHTS.)

Dr. Swinger points up that the vast majority of patients are exceptionally happy following surgery for high myopia, either keratomileusis or epikeratophakia.

#### The Correction of Monocular Aphakia in Children (F-5)

JOHN HUNKELER, M.D., Associate Professor of Ophthalmology, University of Kansas, emphasizes that epikeratophakia is the procedure of choice for monocular aphakia in pediatric patients, especially in the unilateral cataract patient where the need is much greater because of the risk of amblyopia. Clinical results show better predictability and quicker rehabilitation of vision than in adults. Should the initial clinical outcome be insufficient, the surgical procedure can be repeated in the pediatric patient. Aphakia in adults is mostly managed with secondary lens implants.

#### Correction of Keratoconus (F-5)

Epikeratophakia is being used effectively for keratoconus, avoiding the need for penetrating keratoplasty in a good number of cases. In a small percentage of patients, it obviates the need for contact lenses. Usually, though, the patient goes back to contact lens wear, and if not, then sometimes spectacles.

#### The Non-Freeze (BKS) Keratomileusis and Epikeratophakia (F-5)

This is a significant advance in technique because it is an easier and uniformly effective way of using the lamellar techniques of keratomileusis and epikeratophakia without freezing the tissue. This method has been developed by JORG H. KRUMEICH, M. D. from West Germany and CASIMIR SWINGER, M. D., based upon the principles established by Jose Barraquer. The contribution of the non-freeze method is to prevent the healing delay caused by freezing and its consequences. Therefore, it offers faster and more predictable results with more satisfied patients earlier.

#### Prevention and Management of Astigmatism (F-5)

Astigmatism is a complex problem where significant advances have been made with new knowledge on how to prevent it and how to reduce it once it is present. RICHARD TROUTMAN, M. D., Surgeon Director at the Manhattan Eye, Ear & Throat Hospital in New York City, who has dedicated a professional lifetime to cataract and corneal surgery, emphasizes that in cataract surgery, prevention is the most im-

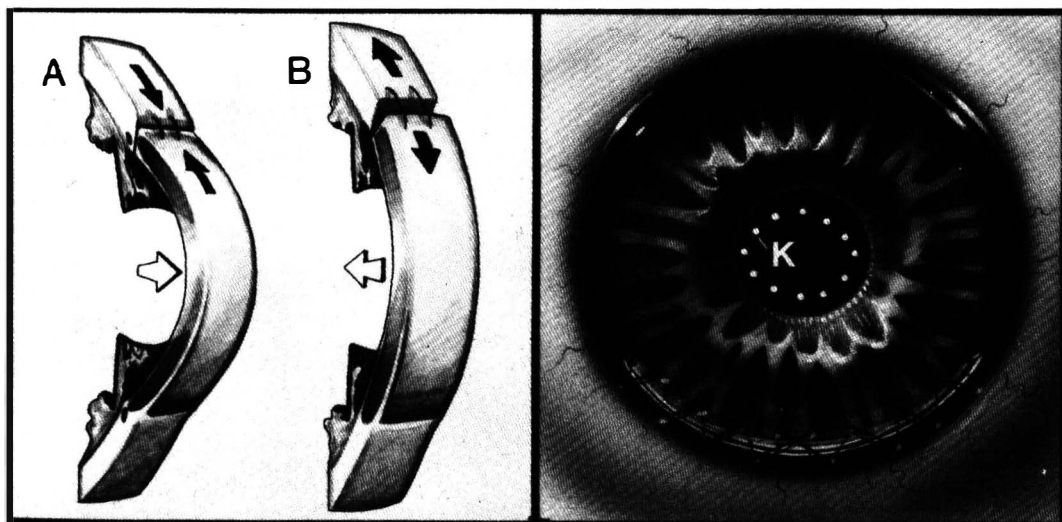


Fig. 4 — Prevention and management of astigmatism in cataract surgery (LEFT) (A) Tight sutures (black arrows) lead to with-the-rule astigmatism by increasing corneal curvature (white arrow) in that meridian. (B) Loose sutures (black arrows) cause against-the-rule astigmatism by flattening (white arrow) the cornea in that meridian. (RIGHT) Tightening of opposing continuous, through-and-through sutures for closure of a cataract incision is monitored with the surgical keratometer (K) to create a slight with-the-rule astigmatism (note horizontal oval shape of keratometer reflections). This astigmatism decays when the continuous sutures are removed about twelve weeks post-op.

portant aspect of astigmatism treatment. The cataract surgeon has to know quantitatively, by keratometer readings, the corneal refractive condition **before** approaching the eye surgically. During surgery, we can, take steps to eliminate a pre-operative astigmatism.

This will **not** significantly interfere with cataract surgical technique nor increase the surgical risk (Fig. 4\*). Otherwise, we would later depend upon secondary procedures to remedy the astigmatism (Fig. 1 — Right and fig. 5 — Left).

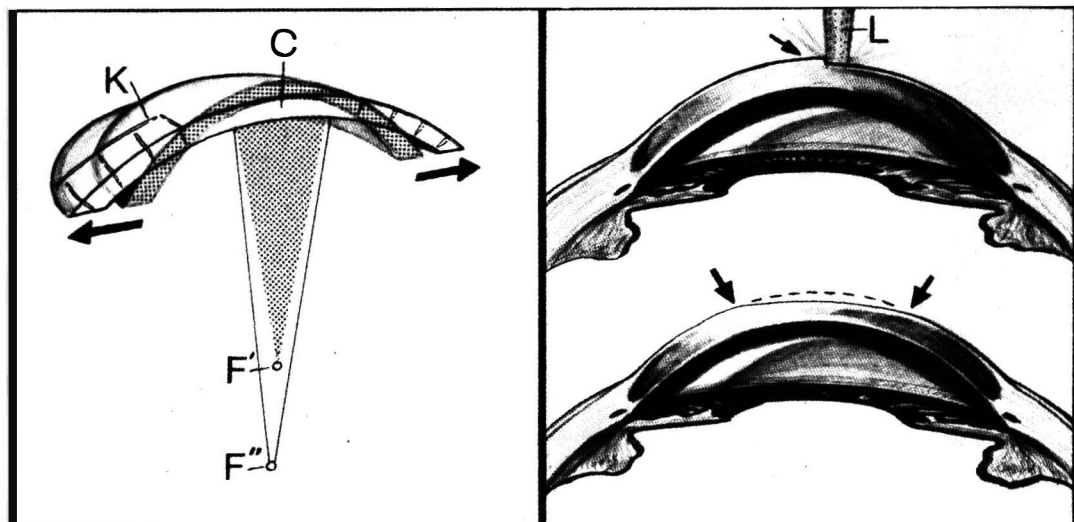


Fig. 5 — Mechanism of astigmatic keratotomies. Keratorefractive surgery with lasers.

(LEFT) Conceptual view shows corneal shape through steep axis pre-op (dot-shaded area) and post-op (white area) following astigmatic keratotomy (K). Corneal fibers have been broken by the incisions to change corneal shape at limbus (arrows) which, in turn, flattens central corneal curvature (C). This flattening of central corneal curvature reduces the refractive power of the cornea in this axis. Pre-op focal point of light (F') has moved posteriorly to (F''). (RIGHT). The excimer laser changes the surface curvature of the cornea (and new optical power) by shaving off thin layers of the central cornea. (Top Left): the laser (L) is removing tissue from central cornea (arrow) of a myopic eye. Result shown below. Tissue has been removed between the arrows to produce a flatter corneal curvature and hence reduce dioptric power. Pre-op corneal curvature shown as dotted line to highlight amount of tissue excised by laser.

In general, it is better to leave the sutures a little tight than loose in cataract surgery. Tight sutures lead to astigmatism with-the-rule, but this can be greatly reduced or eliminated by removing the sutures 3 months after surgery. Removing the sutures before that period of time causes astigmatism against-the-rule (Fig. 4). On the other hand, loose sutures cause astigmatism against-the-rule which, if high, may require corrective surgery for astigmatism or revision and resuture of the wound.

#### Correction of Astigmatism (F-5)

Until recently, our knowledge on how to correct an astigmatism already present was **very limited**. Through the exciting work of LUIS ANTONIO RUIZ, M. D. at the Barraquer Institute of the Americas, we have now a better understanding of how to significantly reduce astigmatism, how to evaluate the patients and predict the results.

The surgery used by Dr. Ruiz to manage astigmatism is in the category of the **relaxing incisions** (Fig. 1) to modify the shape and curvature of the cornea (Fig. 5 — Left\*). He calls these operations **astigmatic keratotomies** and they have different shapes or pat-

terns: **trapezoid** (fig. 1), **inverted trapezoid**, **rectangular**, **diamond** and **fusiform**. The relaxing incisions are placed on the steepest meridian in order to flatten the cornea in that axis.

**Indications and Advantages:** This surgery is indicated and is effective in any type of **congenital astigmatism** and **post-surgical astigmatism** especially after keratoplasty and following cataract extraction. Its great advantage is that we can correct from 0.75 diopters up to 13 diopters of astigmatism and that it can be combined with other refractive procedures to correct or reduce low, moderate and high myopia as well as hyperopia. The patients' recovery is fast sometimes in less than one or two days. (You will find the most extensively illustrated coverage on how to prevent and manage astigmatism in the new Atlas and Textbook, "Refractive Surgery with the Masters, Vol. II, 30 th Anniv. Edition of the HIGHLIGHTS).

#### Keratorefractive Surgery Using Synthetic Materials (F-5)

CHOYCE in England has been the pioneer in this field having operated on 50 patients and RICHARD LINDSTROM, M. D. is the leading researcher in the U. S. They use **intracorneal plastic inlays**, high myopia

being their cardinal indication. This surgery changes the refraction of the eye by altering the power of the cornea on the visual axis, not by altering the shape of the cornea as in radial keratotomy. These inlays are not yet approved by the FDA in the U.S. If eventually approved, this may become a significant operation to correct large refractive errors (+20 to -20 diopters) because it is a relatively simple procedure that could be performed by any ophthalmic microsurgeon.

#### Keratorefractive Surgery with Lasers (F-5)

Many researchers are now turning their attention to using excimer lasers for **surface reprofiling**, that is, shaving off thin layers of the central cornea

to give it a new shape and therefore, new optical power — sort of a “surface keratomileusis” to treat hyperopia, myopia, and astigmatism (Fig. 5 — Right\*). GEORGE WARING, M. D., Professor of Ophthalmology, Emory University School of Medicine, Atlanta, Georgia, one of the world's most prominent refractive surgeons clarifies that the cuts made with an excimer laser are actually **excisions** of tissue, in which tissue is removed from a very narrow trough, and not just incisions as made with the diamond knife.

This research is in its infancy. Presently, in the United States, no laser is approved for experimental use in corneal surgery in humans by the Food and Drug Administration.