

Atypical Corneal Ectasia

Ectasia corneana atípica

Paulo Schor⁽¹⁾
 Angela Chaib⁽²⁾
 Wallace Chamon⁽³⁾
 Denise de Freitas⁽⁴⁾

SUMMARY

We described a 47-year-old man with a noninflammatory bilateral corneal ectasia. Superior thinning was present between 11 and 2 hours, with a localized steep area coincident to the thinning. An edge of apparently non-affected cornea was observed adjacent to the limbus. No deposits, stress lines or deep neovascularization was observed. This case does not match classic descriptions such as keratoconus or pellucid marginal degeneration. Differential diagnosis among noninflammatory ectasia are discussed, focusing in the same-pathology theory.

Key Words: Corneal ectasia; Keratoconus; Pellucid Marginal Degeneration; Corneal Stroma.

Corneal thinning can be divided into two basic groups: inflammatory and noninflammatory pathologies. Among the latter are described keratoconus (KC), pellucid marginal degeneration (PMD), keratoglobus, keratotorus and posterior keratoconus. Noninflammatory corneal thinnings have slow progression, and are normally diagnosed because of decreased visual acuity caused by an induced refractive error.

The authors report a patient with corneal thinning and ectasia, that associate clinical findings among several noninflammatory corneal ectasia.

corrected visual acuity was 20/60 and 20/40 (OD -20.00 sph, and OS -16.75 sph + 1.00 cyl @ 140°). Keratometric mires were irregular in both eyes and measured 36.00 (15°) x 54.00 (105°) in OD, and 37.00 (160°) x 47.00 (70°) in OS. Visual acuity with rigid contact lenses was 20/25 OU. Axial length was 23.35 mm in OD and 23.47 mm in OS.

At the slit-lamp, the corneas presented a superior micropannus and superior thinning between 11 and 2 hours, with a localized steep area coincident to the thinning (fig 1a and 2a). An edge of apparently non-affected cornea was observed adjacent to the limbus. No deposits, Descemet folds or deep neovascularization was observed. Focal ruptures and fleckline scars were observed in Bowman's layer. Ultrasonic pachometry of the superior third of the cornea was OD 0.363 mm and OS 0.409 mm. At all other areas, corneal thickness ranged from 0.525 to 0.618 mm.

Computer-assisted videokerato-

CASE REPORT

A 47-year-old, white, Brazilian man, complaining of progressive decrease in visual acuity since two years ago. The patient had been wearing rigid contact lenses for approximately one year. Uncorrected visual acuity was 20/200 in both eyes, spectacle-

⁽¹⁾ Pós Graduando (doutorado) - Universidade Federal de São Paulo (UNIFESP) Escola Paulista de Medicina (EPM)

⁽²⁾ Médica Oftalmologista

⁽³⁾ Pós Graduando (doutorado) - UNIFESP/EPM

⁽⁴⁾ Doutora - UNIFESP/EPM

From the Department of Ophthalmology, Federal University of São Paulo (UNIFESP) Paulista School of Medicine (EPM), São Paulo Hospital, São Paulo, Brasil.

Author's Address: Paulo Schor, Departamento de Oftalmologia - Escola Paulista de Medicina - R. Botucatu 822, - São Paulo, SP 04023-062

graphy (Corneal Analysis System, EyeSys® Technologies, Houston, TX) presented a superior steep area in both eyes with corneal curvature of approximately 70.00 D within 3 mm from the limbus. There was a compensatory flat region inferior to this protruded area (Fig 1c and 2c), leading to an against-the-rule astigmatism at the central cornea (Fig. 1b and 2b).

This case mixes patterns. It resembles KC and PMD because of the patient's age (40 years), and because it is bilateral.

It is not a classic KC because even with the protrusion being coincident to the thin cornea, the disease is localized superiorly, and there is not a characteristic cone nor stress lines or iron deposits.

The presence of a non-affected corneal edge at the limbus could be considered for the PMD diagnosis. Although its superior localization is still considered unusual, it has been described¹.

Terrien's marginal degeneration should be mentioned in differential diagnosis, regarding the fact that the cornea is clear at the thinning area without lipid deposition.

The denomination of pathologies that course with corneal thinning under a unique name has been proposed based on anatomic and pathological evidences². Keratoconus and PMD present common histopathological findings of total or partial absence of Bowman's membrane as well as stromal thinning and disorganization³. A clinical report of 17 patients with PMD and central KC in the same eye⁴ corroborates to the same-pathology theory.

The authors believe this is a case of

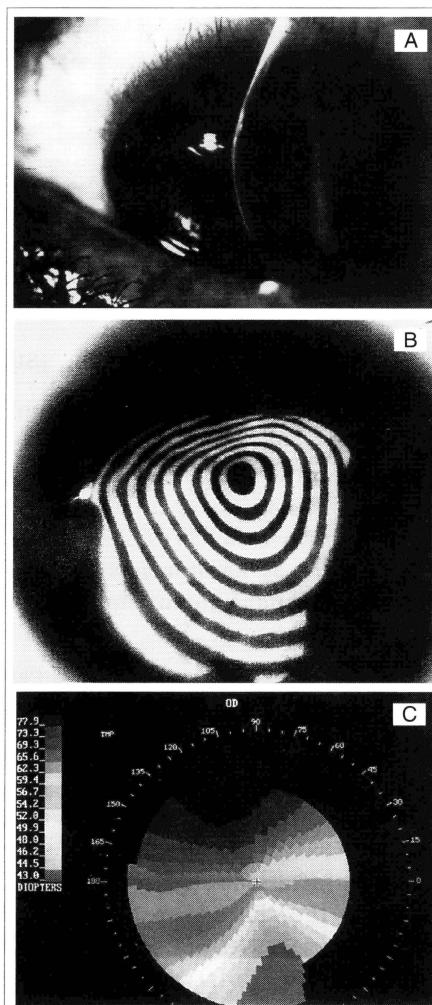


Figure 1 - Right eye clinical appearance (blood vessels are photography artifacts) (A), keratography (B) and computer-assisted videokeratography (C) of a patient with atypical corneal ectasia.

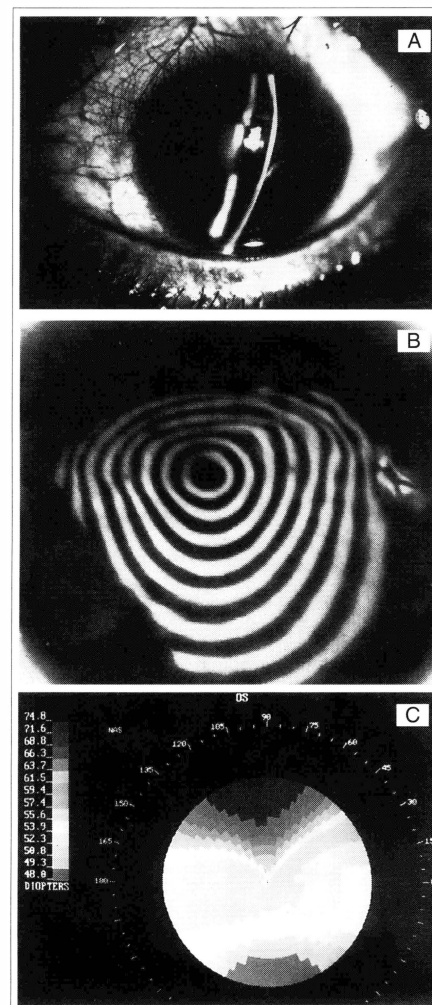


Figure 2 - Left eye clinical appearance (blood vessels are photography artifacts) (A), keratography (B) and computer-assisted videokeratography (C) of a patient with atypical corneal ectasia.

a superior peripheral ectatic corneal pathology that can be diagnosed either as an atypical form of keratoconus or a pellucid marginal degeneration.

REFERENCES

- 1 CAMERON, J. A.; MAHMOOD, M. A. - Superior corneal thinning with pellucid marginal

corneal degeneration. *Am. J. Ophthalmol.*, 109 (4): 486-487, 1990.

- 2 ETZINE, S. - Corneal-thinning syndrome: keratoectyptosis. *Ophthalmologica*, 157: 263-7, 1969.
- 3 KRACHMER, J. H. - Pellucid Corneal Marginal Degeneration. *Arch. Ophthalmol.*, 96: 1217-1221, 1978.
- 4 KAYAZAWA, F.; NISHIMURA, K.; KODAMA, Y. et al. - keratoconus with pellucid marginal corneal degeneration. *Arch. Ophthalmol.*, 102: 895-896, 1984.