

# Radiating folds of Descemet's membrane associated with deep stromal infiltrates<sup>+</sup>

*Dobras radiais da membrana de Descemet associadas com infiltrados profundos do estroma corneano*

Carlos E. Pavésio <sup>(1,2)</sup>  
H. Bruce Ostler <sup>(2)</sup>

## SUMMARY

Star-like folds of Descemet's membrane have been described in association with a phthisical eye and also as a sign of impending perforation. We describe three cases where this change was found in association with deep stromal infiltrates, two of which arose in *Herpes zoster ophthalmicus* and one in *Haemophilus influenza*. The intraocular pressure was normal at the time the folds developed and there was no perforation. We believe the folds are related to cicatricial changes at the level of Descemet's membrane.

**Key Words:** Descemet's membrane; Radial folds; Stromal infiltrates.

## INTRODUCTION

Descemet's membrane is composed of bundles of collagen which have elastic properties that are easily observed by their tendency to retract and curl after rupture. Descemet's folds have been described in stromal keratitis, ocular hypotony or trauma <sup>1</sup>. Herein we describe three cases of radiating or star-like folds of Descemet's membrane associated with deep stromal keratitis associated with herpes zoster ophthalmicus and a bacterial keratitis caused by *Haemophilus sp.*

## CASE REPORTS

### Case 1:

A 76 years-old, white, man gave a history of herpes zoster ophthalmicus which gradually subsided. One year later he developed a dendritiform keratitis in his left eye that evolved into a persistent epithelial defect and a full thickness central infiltrate which caused radiating folds in Descemet's membrane that extended peripherally in a caput medusa pattern (Fig. 1). The central area was scraped and giant

cells identified; gram negative organisms were also recovered but were thought to be contaminants. He was treated with acyclovir 1gr a day (reduced dosage was because of a history of renal failure and dialysis). He gradually improved but continued to have a central epithelial defect thinning of the cornea. The intra-ocular pressure (IOP) was found to be decreased only after the folds had developed. After two months, the central defect gradually healed but the stromal changes and folds persist.

### Case 2:

A 67 years-old, white, female gave a history of herpes zoster kerato-uveitis in 1983 that resolved over one year. In 1986 she developed a red eye, decreased visual acuity with an inferotemporal ulcer and a superficial infiltrate of her left cornea. Scrapings and culture revealed *Moraxella sp* and she was treated with appropriate topical antibiotics. The ulcer enlarged and a deep infiltrate, superficial and deep stromal vessels, and hypopyon developed. The treatment was intensified and the hypopyon disappeared after three days. One month later, radia-

<sup>+</sup> Trabalho realizado na Francis I. Proctor Foundation Universidade da California, San Francisco.

<sup>(1)</sup> Departamento de Oftalmologia Escola Paulista de Medicina, São Paulo, SP

<sup>(2)</sup> Francis I. Proctor Foundation University of California, San Francisco, CA

Endereço para correspondência: Carlos E. Pavésio, M. D. - Moorfields Eye Hospital, City Road, London, EC1V 2PD, UK

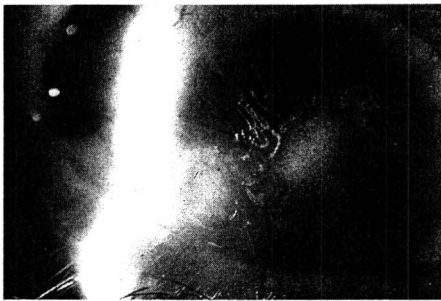


Figure 1 - Central corneal opacity with radiating folds at the level of Descemet's membrane, identifiable by the slit of the parallelepiped. (Case 1).

ting folds of Descemet's membrane, in a caput medusae, were noted starting at the margins of the infiltrate. Her IOP which was initially 18 mmHg dropped to 5 mmHg (after the folds had appeared), the epithelial defect healed, but the folds persist.

#### Case 3:

A 63 years-old, Hispanic, female had a history of chronic open angle glaucoma and was referred due to superficial, central infiltrates and persistent epithelial defect in the right eye. Her examination showed visual acuity of "no light perception" in the right eye with an exotropia and no pupillary reaction to light; the central cornea showed an epithelial defect and four white infiltrates in the anterior stroma; the anterior chamber had a small hypopyon and there were a few keratic precipitates on the endothelial surface.

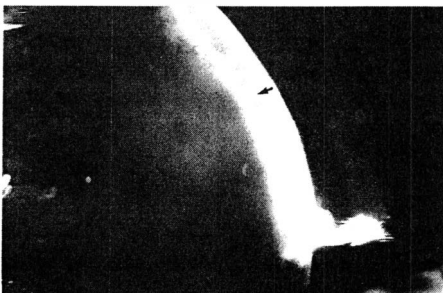


Figure 2 - Radiating folds at the level of Descemet's membrane irradiating from central opacity. (Case 3).

Her laboratory work-up revealed the presence of *Haemophilus sp* and in spite of adequate therapy she involved with deeper infiltrates and a persistent epithelial defect. After extensive antibiotic as well as anti-glaucomatous therapy the epithelium defect closed and she was left with a deep, central, stromal scar and star-like folds of Descemet's membrane were noted radiating from this central area. (Fig. 2).

#### DISCUSSION

Fuchs first described folds at the level of Descemet's membrane as "striate opacity of the cornea" <sup>1</sup>. He described the folds as running at right angles to the axis of a wound. Deep folds have also been described in cases of stromal keratitis <sup>2</sup>. The folds are related to the anatomical structure, elasticity and resistance to physical agents of Descemet's membrane. Folds in hypotonic eyes arise from shrinkage of the supporting structures leading to pressure and fold of this membrane.

Radiating folds similar to our cases were described in a chinese man who had suffered a penetrating injury to his right eye by a piece of bamboo <sup>2</sup>. One year later his cornea was flat, there was a white opacity which involved the entire thickness of the stroma; the folds had a caput medusae pattern. The IOP was very low at the time the patient was first seen, and the eye evolved to phthisis bulbi.

Radiating folds occasionally develop as a sign of impending corneal perforation, in such instances the folds probably represent stress lines resulting from protrusion of Descemet's membrane from the ulcer base <sup>3</sup>.

Two of our patients had herpes zoster keratitis and the third a bacterial keratitis, and the three developed

full thickness infiltrates with radiating folds. The IOP in two of our patients was found to be low only after the folds developed, and therefore the folds were probably not provoked by ocular hypotony. The corneal thickness was never less than 40% of normal thickness, therefore the folds were not related to a Descemetocoele.

We believe that the deep stromal inflammation seen in our cases caused cicatricial changes at the level of Descemet's membrane. Contraction of the cicatricial tissue produced traction lines centered around it, creating the star-like or caput-medusae pattern described, in a similar fashion to epiretinal membrane shrinkage leading to striation of the inner retina <sup>4</sup>.

#### RESUMO

*Dobras radiais da membrana de Descemet já foram descritas em associação com olhos atróficos e também como sinal de perfuração iminente. Os autores descrevem três casos onde essa alteração foi encontrada em associação com infiltrados profundos do estroma corneano, sendo dois deles devidos a infecção por Herpes zoster e um por Haemophilus influenza. A pressão intra-ocular era normal quando do surgimento das dobras e não havia perfuração ocular. Acreditamos que as dobras são devidas a alterações cicatriciais ao nível da membrana de Descemet.*

#### REFERENCES

- 1 FUCHS, E. - Diseases of the Eye. Tenth English edition translated by E.V.L. Brown, 1933, pp. 200-201.
- 2 CHOW, T. T.; CHANG, L. W. - A unique case of radiating folds of Descemet's membrane. *Am J Ophthalmol*, 23(6): 689-92, 1940.
- 3 GOOSEY, J. D.; MOSTELLER M. W.; KAUFMAN, H. E. - Radiating folds in Descemet's membrane as a sign of impending corneal perforation. *Am J Ophthalmol*, 98(5): 625-6, 1984.
- 4 McDONALD, G. R. & SCHATZ, H. - Introduction to epiretinal membranes. In: RYAN, S.J. (ed): *Retina*. St. Louis, C. V. Mosby, 1989, pp. 789-95.