

# Electrocautery of Bowman's membrane for bullous keratopathy

## *Eletrocauterização da membrana de Bowman no tratamento da ceratopatia bolhosa*

Paulo E. C. Dantas<sup>(1)</sup>  
M. Cristina Nishiwaki-Dantas<sup>(2)</sup>  
Cássia Regina Suzuki<sup>(3)</sup>  
Nilo Holzchulz<sup>(4)</sup>  
Silvia Cursino<sup>(5)</sup>  
José Wilson Cursino<sup>(6)</sup>

### RESUMO

**Purpose:** To evaluate the effectiveness and safety of an old procedure (Salleras procedure) in patients with APBK and poor visual prognosis regarding biomicroscopic, histopathologic and tonometric findings.

**Patients and Methods:** Eight consecutive patients with APBK were included and followed up for 3 months. Biomicroscopy and tonometry were taken preoperatively and postoperatively (PO 1, 3, 7, 15, 30, 60 and 90). One patient underwent penetrating keratoplasty and the button was sent to the pathologist.

**Results:** All the patients presented corneal healing in 4 weeks. Their main complaint before the procedure (excruciating pain), was completely alleviated after the corneal healing. There were no IOP increasing out of normal patterns. Histopathologic study showed that the mechanism of action related to this technique is related to formation of a dense connective tissue, that acts as a physical barrier to fluid penetration from the stroma to the epithelium.

**Conclusion:** Besides all technology, electrocautery of Bowman's membrane is still a reliable procedure to treat patients with severe pain and poor visual prognosis in APBK.

**Key words:** Salleras procedure; Bullous keratopathy; Corneal surgery.

### BACKGROUND

Advanced painful bullous keratopathy (APBK) in patients with unsuccessful clinical treatment and concomitant retinal or vitreous disease, in whom the restoration of vision by surgery is not the primary goal, presents a challenge to the ophthalmologist. Moreover, the great majority of these patients are older and have associated systemic disorders such as cardiopathy and diabetes, that represent total contra-indication for major surgical procedures as corneal transplant or conjunctival flaps. Salleras<sup>1</sup> in 1965 described his experience with electrocautery of Bowman's membrane with good results regarding relieving the patient's primary complaint: crucial pain. Complications associated to this procedure are corneal healing problems, definitive corneal flattening, shortening of the anterior chamber and intraocular pressure (IOP) increase.

We prospectively analyzed and followed up 8 consecutive patients submitted to electrocautery of Bowman's membrane for 3 months. IOP variation and biomicroscopy were monitored for this period of time. Histopathologic study was done in one eye of a patient submitted to secondary penetrating keratoplasty.

From Department of Ophthalmology of Hospital da Santa Casa de São Paulo/Brazil.

<sup>(1)</sup> Assistant, Corneal and External Disease Service.

<sup>(2)</sup> Director, External Disease Service.

<sup>(3)</sup> Third year Resident.

<sup>(4)</sup> Director, Corneal Transplant Service.

<sup>(5)</sup> Second year Resident, Ocular Pathology Service.

<sup>(6)</sup> Director, Ocular Pathology Service.

**Correspondence to:** Paulo E. C. Dantas, MD - Rua Martinico Prado 26, conj 181/182 - Santa Cecília - São Paulo (SP) - Brazil - CEP 01224-010. Phone: (5511) 222-1099. Fax: (5511) 606-5306. E-mail: <speyecare@originet.com.br>

## MATERIAL AND METHOD

The inclusion criteria were patients with APBK that did not have improvement with the conventional therapy (osmotic drops and ointment and therapeutic contact lenses) and had poor visual prognosis for corneal transplant. Exclusion criteria were patients with APBK associated to glaucoma or with IOP higher than 21 mmHg prior to the procedure. Eight patients were included in this study (Table 1). Informed consent was signed by all patients, after explanation of the procedure, its risks and benefits.

The technique consisted of the following steps:

- Pre-operative measurement of IOP with Schiötz tonometer. The opposite eye was the control.
- Topical anesthesia with Proparacaine or Tetracaine drops.
- Conventional preparation with lid and skin scrub with Povidine.
- Termocautery applications in a concentric fashion from the center to the periphery of the cornea. We started this step with 0.5 and slowly increased the power of the electrocautery by 0.5 until the Bowman's membrane presented a "stellar pattern" lesion due to its shrinking (Fig. 1).
- At the end of the procedure, we measured the IOP,

applied the therapeutic contact lens and prescribed topical antibiotic (Trimethropin+Sulfa) qid. In our protocol we had established that if the IOP was higher than 21 mmHg immediately after the procedure, we would prescribe oral acetazolamide (Diamox 250 mg) every 8 hours. If the IOP was higher than 30 mmHg, we would perform anterior chamber paracentesis.

g. We followed up these patients in the postoperative days 1, 3, 7, 15, 30, 60 and 90 for IOP measurements, biomicroscopic evaluation regarding corneal epithelization and anterior chamber depth.

One patient (female, 33 years-old) was submitted to a secondary penetrating keratoplasty 4 months later, for cosmetic reasons. The button was examined histopathologically.

## RESULTS

The IOP values and patients characteristics are shown in Table 1. There was no need for oral or topical medication neither paracentesis in any patient. At the slit lamp examination, we observed that the cornea was completely healed in 4 weeks in all patients with a superficial and discrete corneal neovascularization (Fig. 2). Two weeks after the procedure, we observed partial corneal healing in all patients. The depth of the anterior chamber was slightly changed to a flatter pattern but kept the plano-convex shape in all cases. Complete pain relief was noted after the third week and was strictly related to the corneal healing. There were no bullae in the cornea, two weeks after the procedure (Fig. 3). During the first week, the main complaint was foreign body sensation and tearing, that disappeared after 2 weeks.

Hystopathologic study of one cornea (female, 33 years-old, APBK pseudophakic) revealed the substitution of Bowman's membrane for a dense fibroblastic tissue. The endothelial cells were absent, characterizing the main cause of previous bullous keratopathy (Fig. 4). No epithelial bullae were found.

Table 1. IOP values and patients characteristics

PATIENT	PREOP	PO1	PO3	PO7	PO15	PO30	PO60	PO90	MEAN IOP
F,33,P	16	19	19	18	17	17	17	17	17,5
M,65,P	08	11	11	11	11	11	11	11	10,625
F,70,A	15	17	17	17	18	18	18	18	17,25
M,63,A	15	18	18	18	17	17	18	18	17,375
F,63,P	17	17	18	18	17	17	18	18	17,5
F,64,P	16	19	19	17	18	18	18	18	17,875
M,69,A	14	16	16	17	17	17	17	17	16,375
F,68,P	16	16	17	17	18	17	17	17	16,875

F = Female; M = Male; P = Pseudophakic; A = Aphakic; IOP = Intraocular pressure; PO = Postoperative day; Preop = Preoperative day

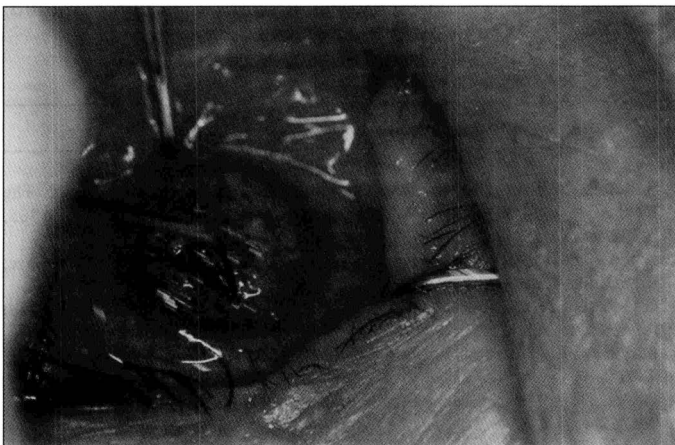

Fig. 1 - Termocautery applications. Note the whitening of Bowman's layer.

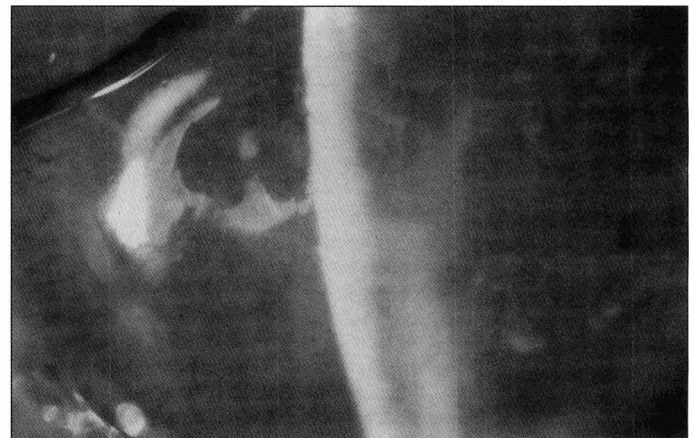

Fig. 2 - Biomicroscopy 4 weeks after the procedure. The epithelium is completely healed.

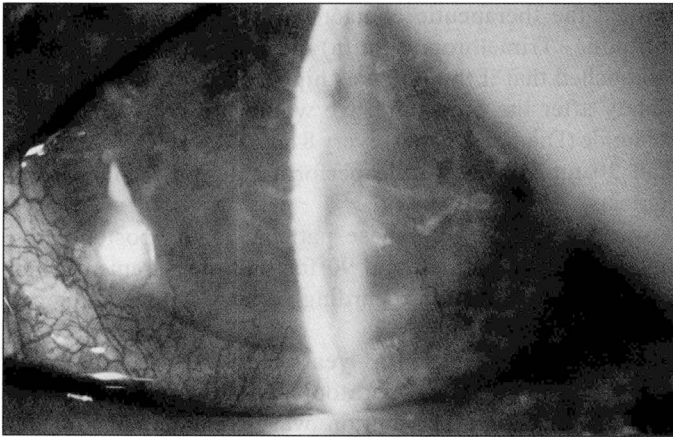


Fig. 3 - Biomicroscopy 4 weeks after the procedure. There were no bullae in the stroma or epithelium.

### DISCUSSION

APBK is still a challenge to the anterior segment surgeon nowadays. Depending on the symptoms and stage, many forms of treatment are available such as hypertonic drops and ointment, therapeutic contact lenses<sup>3</sup>, conjunctival flaps<sup>4</sup> and penetrating keratoplasty. There remains a significant group of patients in whom restoration of vision by surgery is not the primary goal and the clinical conditions of the patient does not allow major surgical procedures. The relief of excruciating pain is the main goal. In 1965, Salleras<sup>1</sup> proposed to treat patients with APBK with electrocautery of the Bowman's membrane, but the basic idea came from Parker<sup>5</sup> in 1894 with the use of light application of galvanotherapy to the entire corneal surface. De Voe<sup>5</sup> in 1966 did histopathologic study in 2 eyes that were submitted to electrocautery of Bowman's membrane and noted the formation of a dense connective tissue plaque beneath the epithelium and a visible fibrocytic response. Recently, Koenig<sup>6</sup> proposed annular keratotomy as a useful procedure to treat APBK, however two




Fig. 4 - Histopathologic plate showing a dense fibroblastic tissue beneath the epithelium, replacing the Bowman's membrane. There were no epithelium bullae.

of three treated eyes developed an increase of central corneal thickness induced by corneal edema. Moreover, the cornea still presenting bullous keratopathy, with the risk of infection of the ruptured bullae. Besides the slight flattening of the cornea, we did not experience significant IOP increase in our patients. The cornea was partially healed in 2 weeks and completely healed in 4 weeks without complications. The main complaint of these patients was foreign body sensation during the first week, probably due to nude cornea. The pain relief was total in 2 to 3 weeks. In one patient we performed a corneal transplant for cosmetic reason (female, 33 years-old) 3 months after the procedure and the button was sent to the pathologist. Absence of endothelial cells was noted and characterized the cause of the edema. The substitution of Bowman's membrane for a thick connective tissue probably plays a role as a mechanic barrier to penetration and flow of fluid from the stromal layer to the epithelial cells, avoiding the formation of new bullae.

Electrocautery of Bowman's membrane in our experience demonstrated to be a safe, easy to do and reliable procedure to treat APBK, and besides all advanced technology, it is still our procedure of choice for eyes with APBK and poor visual prognosis. We think that selecting patients with normal anterior chamber and IOP lower than 21 mmHg would help the surgeon avoiding complications related to the corneal flattening associated with this technique.

### RESUMO

*Ceratopatia bolhosa dolorosa avançada em pacientes não controlados clinicamente e portadores de doenças oculares com mau prognóstico visual, como descolamento antigo de retina e doenças crônicas do vítreo, nos quais o alívio da dor é o principal objetivo, podem se beneficiar de uma antiga, mas eficaz e acessível forma de tratamento, a eletrocauterização da Membrana de Bowman (Procedimento de Salleras).*

*Realizamos estudo prospectivo em 8 pacientes consecutivos submetidos ao procedimento no tocante à biomicroscopia, tonometria e histopatologia.*

### REFERENCES

1. Salleras. Bullous Keratopathy. In: King JH and McTigue JW eds. The Cornea, World Congress, Washington D.C.: Butterworth & Co, 1965, p.292-9.
2. Leibowitz HM, Rosenthal PR. Hydrophilic contact lenses in corneal disease, II: bullous keratopathy. Arch Ophthalmol 1971;85:283-5.
3. Gundersen T. Conjunctival flaps in the treatment of corneal disease with reference to a new technique of application. Arch Ophthalmol 1958;60:880-8.
4. Parker WR. Galvanocautery in bullous keratitis. Ophthal Rec 1894-1895; 4:66-9.
5. De Voe AG. Electrocautery of Bowman's membrane. Arch Ophthalmol 1966; 76:768-71.
6. Koenig SB. Annular keratotomy for the treatment of painful bullous keratopathy. Am J Ophthalmol 1996;121:93-4.