

Corneal epithelial healing in rabbit eyes with partial corneal-conjunctival and conjunctival limbal deficiency

Cicatrização epitelial corneana em olhos de coelhos com deficiência parcial de limbo corneo-conjuntival e conjuntival

Diane Ruschel Marinho ⁽¹⁾
Ana Luisa Höfling de Lima ⁽²⁾
Sérgio Kwitko ⁽³⁾
Martin Kirst ⁽⁴⁾
Jeanine Mársico ⁽⁵⁾
Daniela Roehe ⁽⁶⁾

SUMMARY

Purpose: To compare corneal epithelium healing of rabbit eyes with partial keratoconjunctival and conjunctival limbal deficiency with normal corneas (controls).

Methods: Partial limbal deficiency (PLD) was created by surgical removal of one third of the superior limbal zone by performing a partial-thickness corneal incision at 2 mm from the limbus (Group 1) and by the removal of conjunctival limbus without corneal dissection (Group 2). All operated eyes and control underwent two consecutive alkali burns.

Results: After the two alkali burns, the eyes of Group 1 had a delayed epithelial healing curve when compared with controls ($p < 0.05$); eyes of Group 2 and the controls had similar healing curves. Corneas of both groups showed greater vascularization than controls but there was no significant difference. The occurrence of stromal transient opacities was greater in Group 1 when compared with controls ($p < 0.05$). There was only one case of permanent opacity, vascularization and persistent epithelial defects that belonged to Group 1. Cytologic evaluation showed normal epithelial corneal cells except for one case of Group 1 which showed goblet cells on the superior cornea.

Conclusions: These results support the concept that in PLD corneas the epithelium is still impaired after a moderate corneal burn and that keratoconjunctival limbal removal causes a worse PLD than conjunctival limbal removal, a relatively less invasive procedure.

Keywords: Limbal transplantation; Limbal deficiency; Chemical injuries; Stem cells.

INTRODUCTION

Like other body surfaces, the cornea is in a constant state of regeneration. When the balance is disrupted, as it dramatically occurs after a chemical burn, the corneal epithelial healing process is established. Such a response represents an exacerbation of the normal physiological process, involving cellular and subcellular events occurring under the influence of extracellular matrix proteins and growth factors ¹.

Studies on cell kinetics have indicated the presence of a proliferative cell compartment, also present on the ocular surface, consisting of stem cells (SC) and transitional amplifying cells (TAC) ².

Only by using monoclonal antibodies could the exact anatomical location of SC in the limbal basal epithelial layer be elucidated by Schermer et al.³.

⁽¹⁾ Mestre em Oftalmologia pela Universidade Federal de São Paulo (UNIFESP) - Escola Paulista de Medicina.

⁽²⁾ Mestre e Doutora em Oftalmologia e Professora Adjunta do Departamento de Oftalmologia da Universidade Federal de São Paulo (UNIFESP) - Escola Paulista de Medicina.

⁽³⁾ Mestre e Doutor em Oftalmologia pela Universidade Federal de São Paulo (UNIFESP) - Escola Paulista de Medicina.

⁽⁴⁾ Residente do 1º ano do Serviço de Oftalmologia do Hospital de Clínicas de Porto Alegre, Universidade Federal do Rio Grande do Sul.

⁽⁵⁾ Estagiária do Serviço de Oftalmologia do Hospital de Clínicas de Porto Alegre, Universidade Federal do Rio Grande do Sul.

⁽⁶⁾ Acadêmica da Faculdade de Medicina da Universidade Federal do Rio Grande do Sul.

Address for correspondence: Dra. Diane Marinho - Rua Quintino Bocaiuva 1394/602, Porto Alegre (RS), CEP 90440-050. Email: diane@portoweb.com.br

Ebato et al.^{4, 5} showed that the epithelial cells from the peripheral cornea grow much better in tissue culture than those derived from its central part and that limbal cell mitotic activity is significantly greater than that of peripheral corneal cells.

Several authors have then speculated that SC should play a crucial role as sources of corneal epithelial differentiation and proliferation. Huang and Tseng⁶, through experimental studies on rabbits, observed that, after surgical removal of the whole limbus, including 2 mm of the peripheral cornea and 3 mm of adjacent conjunctiva, there was appearance of persistent epithelial defects and corneal vascularization when the cornea was subsequently submitted to two consecutive epithelial defects.

The corneal surface may be severely impaired by chemical burns, specially alkaline burns, Stevens-Johnson syndrome and Lyell's syndrome. These diseases lead to important SC destruction. Corneal reepithelization is pathologically effected generating a true corneal "conjunctivalization" with keratinization and neovascularization, persistent epithelial defects, trophic ulcers, corneal necrosis and even perforation.

Kenyon and Tseng⁷ were the first to report better clinical results by means of the inclusion of limbal epithelium in their autologous conjunctiva transplantation for several unilateral diseases of the ocular surface, such as chemical burns, contact lens induced keratopathies and recurrent pterygium. The surgical technique recommended by these authors for obtention of donor grafts involves the sectorial removal of limbal tissue including approximately 0.5 mm of clear cornea, centrally, and, at least, 2 mm bulbar conjunctiva, peripherally. Authors such as Durand et al.⁸, Ronk et al.⁹, Tan et al.¹⁰, among others, also obtained good results with their autologous limbal transplantation series, using the technique described by Kenyon and Tseng⁷.

The donor graft to be transplanted may be removed from the contralateral eye, in cases of unilateral disease (autologous transplantation) and, in bilateral cases, from eyes of relatives (allogeneic transplantation) after previous HLA matching¹¹ or from a cadaver donor (allogeneic transplantation) associated with systemic immunosuppression^{12, 13}. Healing of donor eyes is, generally, rapid and postoperative complications are rare.

There are few studies on corneal reepithelization in eyes with partial limbal deficiencies. According to an experimental study by Chen and Tseng¹⁴, partial removal of the limbal region, similar to the obtention of donor grafts for a limbal transplantation, impairs the corneal surface which may suffer decompensation and develop a limbal deficiency after a later epithelial defect.

Some authors^{11, 15-18} showed good results by performing conjunctival limbal transplantation without keratectomy. This technique differs only regarding obtention of donor grafts. Removal of perilimbal conjunctiva, without Tenon's capsule is performed using conjunctival scissors. Limbal conjunctiva graft is removed from its corneal insertion, the closest possible to the limbus. It is possible that without keratectomy,

limbus donors develop a slighter limbal deficiency, without impairing the surgical result in the receptor eye and avoiding complications of a future epithelial defect. In addition this is a simpler technique with less risk to the donor eye.

Our purpose was to compare the corneal epithelization process in rabbit eyes with partial conjunctival limbal and corneal-conjunctival deficiency.

MATERIALS AND METHODS

This experiment was carried out according to the ARVO norms and was approved by the Ethics Committees of the Hospital de Clínicas de Porto Alegre and UNIFESP. Sixty eyes from thirty male albino rabbits, weighing from 1980 to 2700 g, were used. Three groups of equal size were formed. Selection of rabbits was at random in the three groups: Group 1, Group 2 and Group 3 (control), each consisting of 20 eyes. Twenty eyes from 20 rabbits formed Group 1 and were submitted to removal of a corneal-conjunctival limbus graft. The 20 contralateral eyes of these 20 animal formed Group 2 and were submitted to removal of the conjunctival limbus. Twenty eyes from 10 rabbits formed Group 3 (control group) and did not suffer any surgical procedure.

Surgical technique

Surgeries were carried out by the same surgeon using a surgical microscope, adequate instruments and asepsis technique. General anesthesia with intramuscular atropine and Zoletil® 50 (125 mg tiletamine hydrochloride + 125 mg zolazepam hydrochloride) was used.

Group 1 - Removal of limbal corneal-conjunctival flap:

A 10 x 5 mm superior conjunctival flap (from 10 to 2 h) was removed including 2 mm peripheral keratectomy according to the technique described by Kenyon and Tseng⁷ for donor tissue removal in limbus transplantation. Initially, a partial corneal incision (1/3 of the corneal thickness), 2 mm from the limbus, was made using a Beaver #69 blade, followed by lamellar dissection towards the limbus with a #66 blade and removal of 3 mm conjunctiva beyond the limbus with conjunctiva scissors.

Group 2 - Removal of conjunctival limbal flap:

A 10 x 4 mm superior conjunctival flap (from 10 to 4 h) was removed including only conjunctival limbus without keratectomy. The surgical technique was that described by Pfister¹⁸ and by Kwitko et al.¹¹, where a conjunctival flap adjacent to the limbus is removed close to its insertion in the cornea.

During the postoperative period, eye drops consisting of association of dexamethasone with neomycin were used three times daily for approximately 15 days in both groups. The eyes were examined daily, with topic fluorescein until complete corneal conjunctival healing.

Application of corneal burns

Twenty-one days after surgery all thirty rabbits, including those of the control group, were anesthetized as mentioned above. A bilateral corneal burn was applied to the three groups through instillation of two drops of 0.5 N NaOH solution for 30 seconds, followed by continuous washing with 0.9% physiological saline for 1 minute (500 ml). Thereafter 1 drop of fluorescein was applied in order to confirm complete removal of the corneal epithelium.

Twenty-five days after the first burn, the rabbits were submitted to a second alkaline burn applied in the same manner. All results were evaluated equally in 56 eyes after the first burn (36 eyes divided equally between Groups 1 and 2 and 20 eyes in Group 3). After the second burn, 48 eyes (16 in each group) were effectively studied.

The rabbits were examined daily after application of the alkaline burns until complete healing of the epithelial defect. An external examination was performed with serial photographs, using fluorescein eyedrops for follow-up of the corneal healing. Every two days, starting from the first day after the burns, the examinations were photographically accompanied (Figures). The photographs were standardized using a Dental-Eye II camera, with a zoom of 2 times and a 1:1 objective.

Dependent variables studied

All observations were made by 2 knowledgeable and independent observers, which were unaware of both the employed surgical procedure and interpretation of the other observer.

1. *Speed of corneal reepithelization*: in days until complete healing of the epithelial defect.

2. *Healing curve*: obtained by drawing the mean and standard deviations of the epithelial defect area on each postoperative day ¹⁴. Epithelial defect area was calculated in mm² from the projection of the slide of each rabbit on a standardized screen divided into millimeters, which was photographed in the same manner as the slides of the animals. Location of the residual epithelial defect was also observed.

3. *Corneal vascularization*: calculated according to the classification recommended by Thoft et al. ¹⁹:

- 0 = without vessels
- 1+ - vessels up to 2 mm from the limbus
- 2+ - vessels up to 4 mm from the limbus
- 3+ - vessels up to 6 mm from the limbus
- 4+ - vessels in the visual axis

4. *Alteration in corneal transparency*: based on the classification by Hughes ²⁰:

- Discrete = light opacity allowing vision of iris details.
- Severe = making vision of iris details difficult.
- Very severe = opacity hindering vision of pupil area.

5. *Ocular surface cytology*: carried out immediately after closing of the epithelial defect after the two burns. Material was removed from the superior third of the corneal surface of 3 eyes from each group, always from those which took longest

to heal in each group. For removal of the material we used a small nylon brush like that utilized for cervical cytology (Cytobrush®). After collection of the material the brush was washed in 0.9% physiological saline and the washing submitted to centrifugation for the obtention of cytology specimens, which were stained by the method of Papanicolaou associated with PAS ²⁰.

6. *Appearance of other complications*: occurrence of corneal or conjunctival lesions such as recurrent erosions or granulomas.

Statistical analysis

A descriptive analysis, characterizing the studied population, was carried out. The characteristics were presented in the forms of graphs and tables. For the analysis of the sequential measurements, repeated measurement analysis (ANOVA) and Wilks' test was used for multiple comparisons.

Comparisons of other variables between the three studied groups were made using Kruskal-Wallis' nonparametric test. For the analysis of healing time and curve (variables with normal distribution) between operated and nonoperated eyes, Student's t test was used. Comparisons of stromal opacities and induction of vascularization between operated and nonoperated eyes were made using the qui-squared test. Comparisons with $p < 0.05$ were considered statistically significant.

RESULTS

After the first burn, two animals died for unknown reason, not related to the experiment, thus totaling 18 eyes evaluated in Group 1 (removal of the corneal-conjunctival limbus), 18 eyes in Group 2 (removal of the conjunctival limbus) and 20 controls (Group 3). After the second burn, another 8 eyes from 4 animals were excluded due to possible respiratory infection (2 eyes from Group 1, 2 from Group 2 and 4 from the control group, totaling 16 eyes evaluated in Group 1, 15 in Group 2 and 16 controls. All animals were followed-up at least for 60 days after the second burn.

All eyes submitted to surgery (Groups 1 and 2) healed rapidly in 4 to 7 days without leaving any kind of corneal surface damage. Corneal epithelium and surface of these eyes remained intact and transparent during the entire follow-up of 21 days. All eyes submitted to the second burn healed without sequelae in the ocular surface.

Evaluation of corneal epithelial healing time

After the first burn, operated eyes (Groups 1 and 2), when analyzed together, healed on average in 5.0 ± 0.36 days. The difference between this healing time and that of the control group (3.7 ± 0.44 days) showed to be statistically significant ($p = 0.02$). Despite the fact that the healing time of Groups 1 and 2 was longer than that of the control group, the differences in healing time between the 3 groups (Table 1) were not significant ($p > 0.05$).

Table 1. Corneal epithelial healing time after the first burn.

Group	n	Healing time (days) mean / median	p value*
1	18	5.2 / 5.0	0.15
2	18	5.0 / 4.0	
3	20	3.7 / 3.5	

* Kruskal-Wallis Test.

Table 2. Corneal epithelial healing time after the second burn.

Group	n	Healing time (days) mean / median	p value*
1	16	7.5 / 5.0	0.17
2	16	5.5 / 5.0	
3	16	4.0 / 3.0	

* Kruskal-Wallis Test.

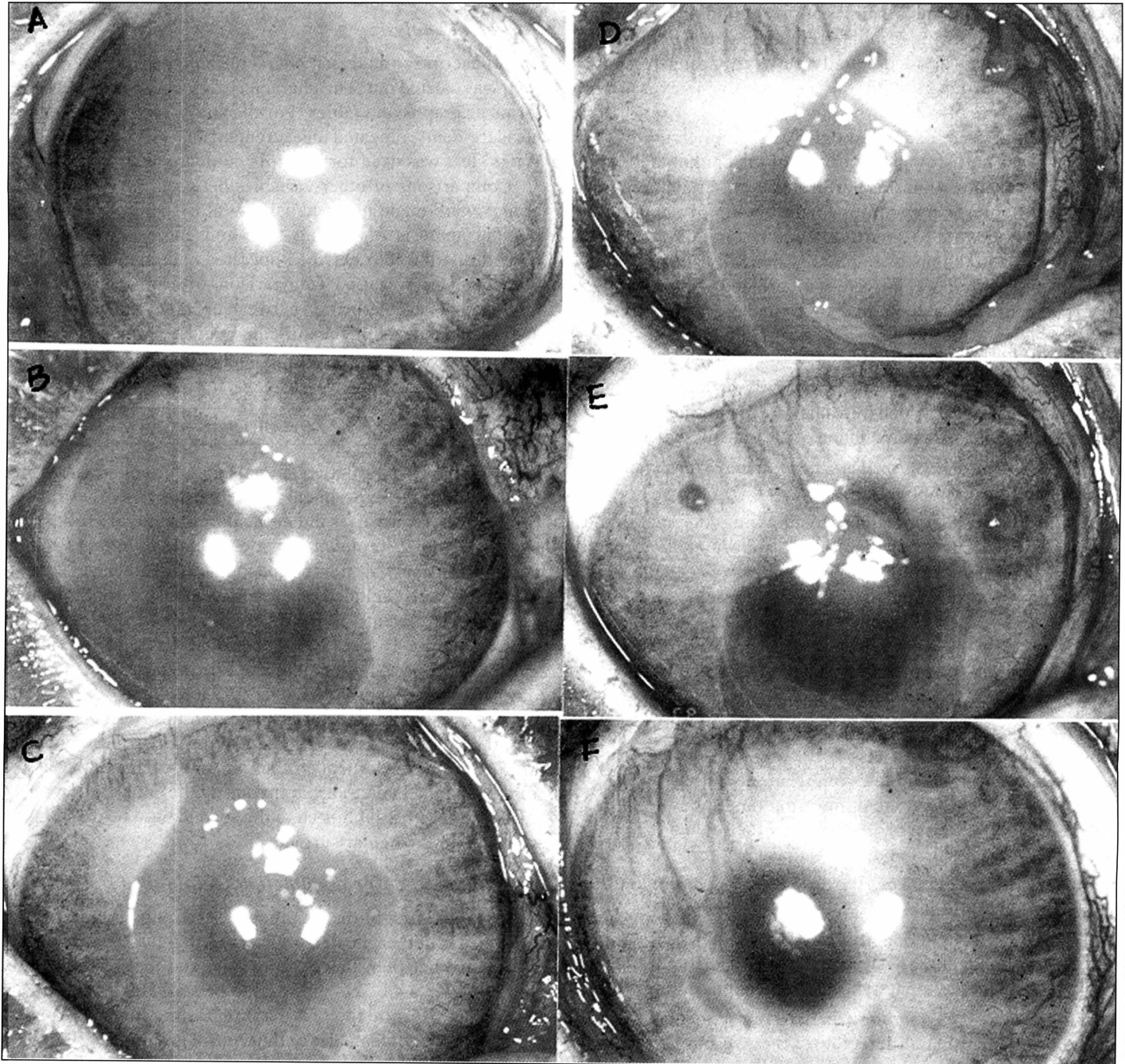
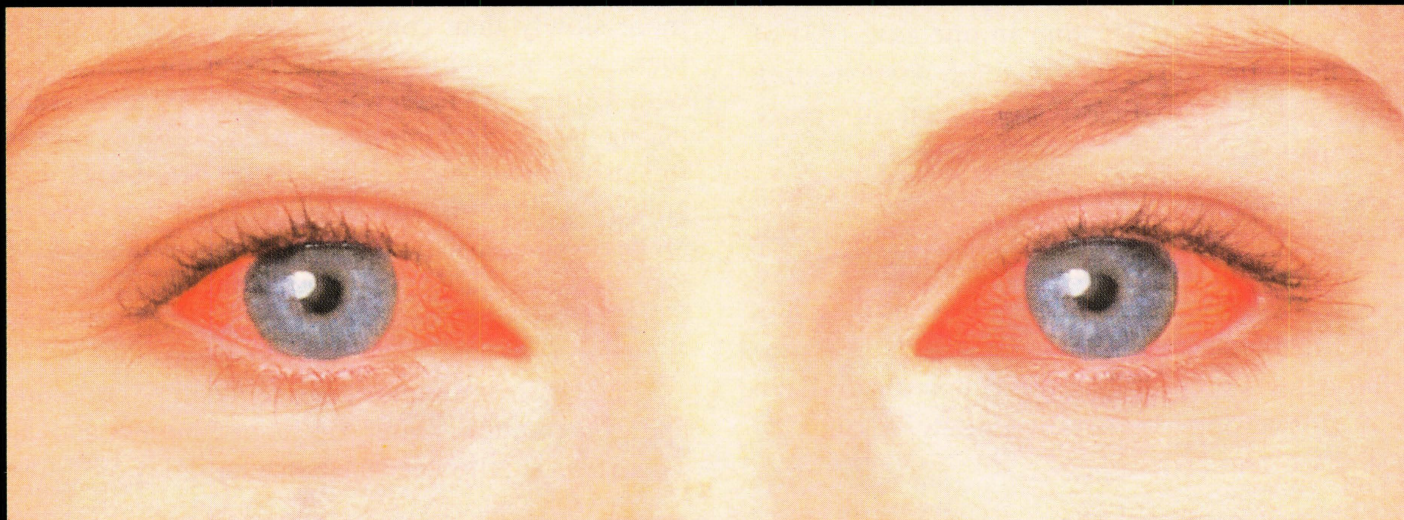

Fig. 1 - Case 2 of Group 1 (removal of corneal-conjunctival limbal flap). Corneal healing on day 1 (A), day 3 (B), day 7 (C), day 9 (D), day 11 (E) and day 20 (F) after the second burn.



Conjuntivite alérgica.

- Prurido
- Hiperemia
- Dor
- Inflamação

The healing time after the second burn was on average 6.5 ± 1.0 days for Groups 1 and 2 together. This result showed to be significant ($p = 0.02$) when compared with the controls.

Table 2 shows the mean healing time for the 3 groups. A great variation, shown by the high standard error, occurred in Group 1, due probably to the fact that healing of the epithelial defect of two eyes from this group took 31 and 21 days (cases 2 and 11). The healing sequence of case 2 (Group 1) is shown in Fig. 1. Healing in one case (#3) of Group 2 took 13 days. In spite of the greater delay in healing of Group 1, there was no statistically significant difference between the groups.

After the first and second burns in both Group 1 and Group 2, the epithelial defect of the superior corneal third, adjacent to limbus removal was the last to heal in 69.5% and 75.3% of the cases, respectively (Fig. 2A and 2B). In the control group, 34.0% (after the first burn) and 38.3% (after the second burn) of the epithelial defects healed last in the superior third. In most cases of this group, the epithelial defect healed centripetally (Fig. 2C and 2D).

Evaluation of the epithelial healing curve

The healing curve (which besides time also registers the epithelial defect area) of the limbal deficient eyes of Groups 1 and 2, analyzed together, and of the controls is presented in Fig. 3. There was a significant difference only on the first day after the first burn.

Comparing separately the healing curves of each group after the first burn (Fig. 4), eyes submitted to partial corneal and conjunctival limbal deficiency (Groups 1 and 2) healed more slowly than controls ($p = 0.04$ between groups), but there was no significant difference on comparing Group 1 with Group 2. There was a significant difference between Group 1 and the control groups at all times observed, while this difference was only significant between Group 2 and the control group on day 3 of observation. The method of "repeated measurement analysis" and Wilks' test was used in this analysis to evaluate multiple comparisons between groups. The same analysis was used to evaluate the results shown in Fig. 6.

The healing curve of the operated eyes (Groups 1 and 2), and of the controls after the second burn is shown in Fig. 5. There was significant difference until day 5 of observation.

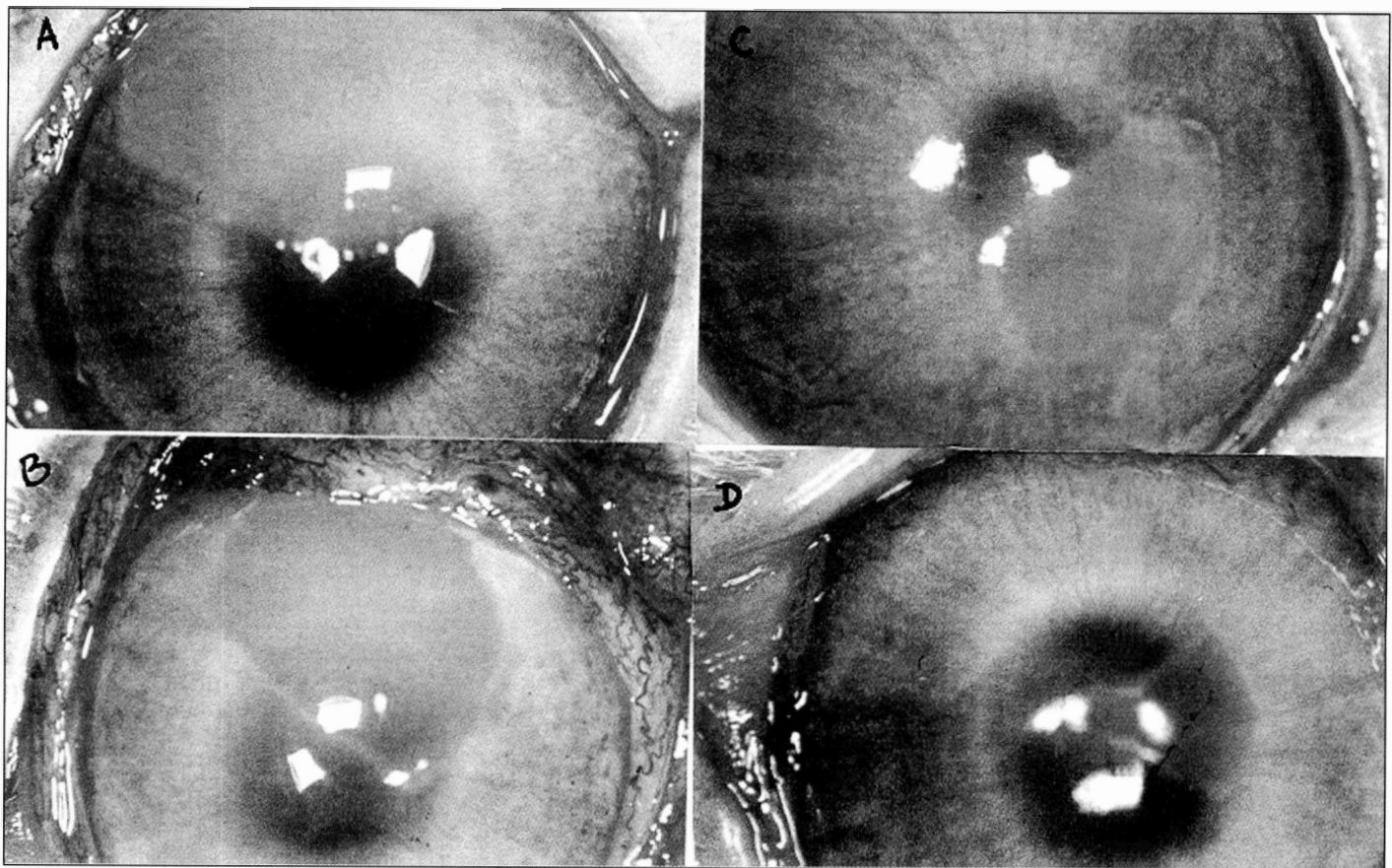



Fig. 2 - Case 5 of Group 2 (removal of conjunctival limbal flap) on day 5 (A) and day 7 (B) after the second burn. Case of the control group on day 5 (C) and day 7 (D) after the second burn.

ACULAR®

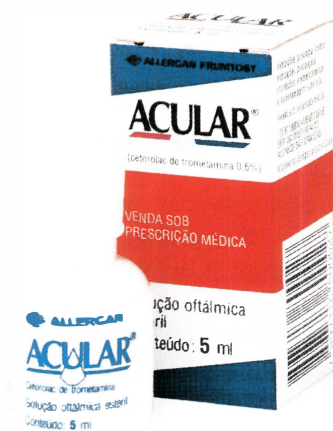cetorolac de trometamina 0,5%

Alívio num piscar de olhos.



PROPORCIONA RÁPIDO CONFORTO E
ALÍVIO DO PRURIDO E DA HIPEREMIA OCULAR
ASSOCIADOS À CONJUNTIVITE ALÉRGICA

- ▶ Promove maior e mais rápido conforto.
- ▶ Promove rápido alívio do prurido e da hiperemia.
- ▶ Alivia os sintomas crônicos e prolongados da alergia ocular.
- ▶ Representa uma boa alternativa à terapia com corticóides.
- ▶ Inibe a cicloxigenase e bloqueia a síntese das prostaglandinas.



- Apresentação: Frasco plástico (conta-gotas) contendo 5 ml.

Referências Bibliográficas: Consulte nosso departamento médico.

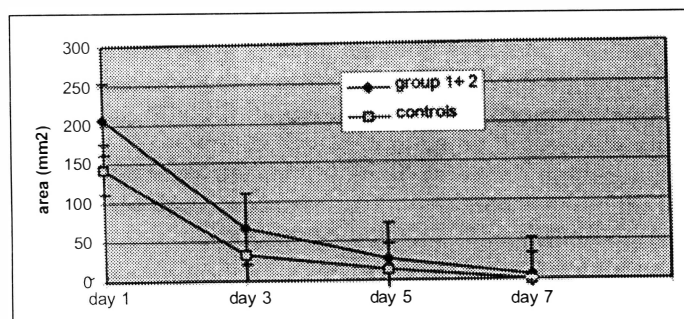


Fig. 3 - Corneal healing curve of eyes with limbal deficiency and controls after the first burn. There was a statistically significant difference between the two groups ($p < 0.05$) on day 1.

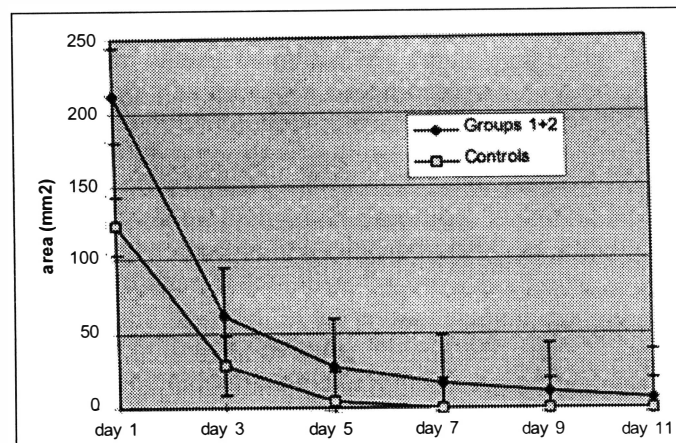


Fig. 5 - Corneal healing curve of eyes with limbal deficiency and the control group after the second burn. There was a statistically significant difference between the two groups ($p < 0.05$) until day 5.

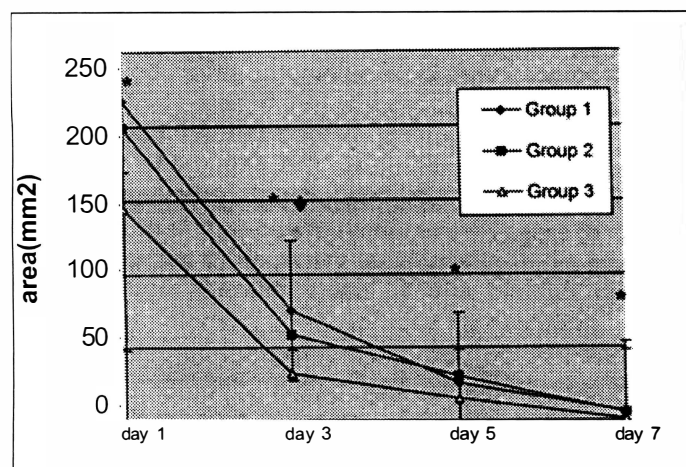


Fig. 4 - Corneal healing curve of the three studied groups after the first burn. There was a statistically significant difference ($p < 0.05$) between Group 1 and controls on all days of observation (*). Between Group 2 and the controls only on day 3 there was a statistically significant difference (♦).

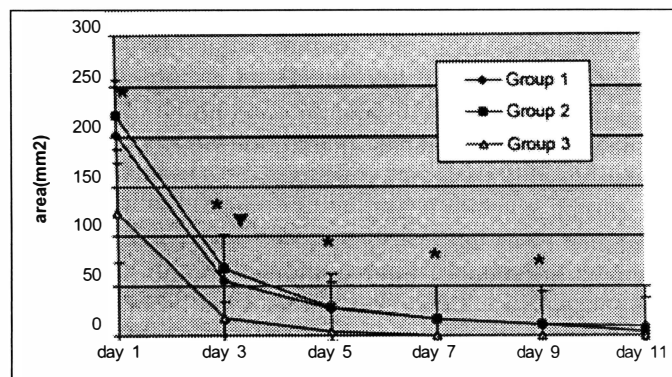


Fig. 6 - Corneal healing curve of the three groups after the second burn. Up to day 9 of observation there was a statistically significant difference between Group 1 and controls (*). Between Group 2 and the control group only on day 3 there was a statistically significant difference (♦).

On analyzing the epithelial healing curve between the three groups, after the second burn (Fig. 6), a more evident delay in corneal healing of Groups 1 and 2 as compared to the controls can be observed ($p = 0.02$ between the 3 groups). Regarding the different times, it can be observed that Group 1 healed more slowly than the controls, with significant difference on all days of follow-up. Comparing Group 2 with the control group, there was statistically significant difference only on day 3. Groups 1 and 2 healed similarly, mainly after day 5.

Evaluation of the corneal vascularization

After the first burn we observed superior peripheral corneal vascularization in one case (5.5%) of Group 1 and in 2 cases (11.1%) of Group 2. All these eyes presented vessels, maximally at 2 mm from the limbus, classified as 1+. There was complete regression of the vessels at the end of the follow-up. No vascularization occurred among the controls.

After the second burn, 3 (18.7%) eyes of Group 1 presented vessels at the superior cornea with 1+, 2+ and 3+ vascularization, respectively. Also in 3 eyes of Group 2 vessels were observed at the superior periphery, all classified as 1+. One eye (6.2%) of the control group developed vessels (1+). In all eyes of the three groups which showed vessels at 4 mm from the limbus (1+ and 2+) there was regression. In case 2 of Group 1, with 3+ vascularization, the vessels remained up to the end of follow-up (Fig. 1F).

After the two burns, the comparative statistical analysis showed that there were no differences between the three groups regarding induction of vascularization ($p > 0.05$). Comparing Groups 1 and 2 together with the control group, there was also no significant difference.

Evaluation of corneal transparency

After the first burn there were 5 (27.7%) cases of transient corneal opacity, lasting on average 3 days (ranging from 2 to

3 days). In Group 2, three transient opacities (16.6%) were observed lasting on average 4 days (ranging from 2 to 6 days). All cases, in both groups, appeared soon after epithelial defect healing and were classified as discrete, according to Hughes²⁰. No rabbit from the control group presented stromal opacity during the observation period. Comparison between the three groups was significant ($p < 0.05$). The difference found between Groups 1 and 2 and between Group 2 and the control group was not statistically significant, however, that between Group 1 and the control group was significant ($p = 0.04$).

After the second burn, there were 7 eyes (43.7%) with corneal opacity in Group 1, lasting on average 21 days (ranging from 3 to 60 days). Of these cases, 28.6% were classified as severe and 71.4% as discrete. One of the two severe cases persisted until the end of follow-up (60 days). In Group 2, 7 (43.7%) cases of transient corneal opacity were observed, persisting on average for 12 days (ranging from 3 to 17 days). Only one (14.3%) of these cases was severe and the remaining 85.7% were discrete. In Group 3, the control group, there was only one (6.2%) case of discrete opacity lasting 9 days. Comparative statistical analysis between Groups 1 and 2 and the control showed a borderline significance ($p = 0.07$).

Comparison of frequency of stromal opacities among the operated eyes (Groups 1 and 2) with controls showed a significant difference ($p = 0.04$) after the two burns.

Cytologic evaluation of the ocular surface

Corneal cytology performed after healing of the epithelial defect showed the presence of normal squamous epithelial cells in all cases of the three studied groups. In case 2 (Group 1), the only case of persistent corneal "conjunctivalization" in addition to squamous epithelial cells a small number of goblet cells was evidenced in the superior corneal third.

Appearance of complications

A persistent corneal stromal opacity remained only in one eye of Group 1 (case#2) which presented recurrent erosions and 3+ vascularization until the end of the study (60 days after the second burn) (Fig. 1F).

DISCUSSION

As shown by Tsai et al.²² limbal transplantation is more efficient regarding reconstruction when compared with bulbar conjunctival transplantation. These results were determinant in demonstrating that limbal stem cells are the most qualified to functionally restore "conjunctivalized" ocular surface in diseases with limbal damage.

Since then several clinical studies showed good results utilizing the new limbal transplantation technique. Many series utilized the original technique of Kenyon and Tseng⁷ for autologous limbal transplantations^{8-10, 23} or for allogeneic transplantations¹¹. The technique utilized in those studies recommends a peripheral keratectomy including 0.5 to 1 mm

of clear cornea to obtain the donor graft. This surgical technique was utilized in Group 1 animals.

Concomitantly, other authors reported equally satisfactory results of reconstructing the corneal surface utilizing conjunctival limbal grafts (autologous or allogeneic from live donors) without peripheral keratectomy^{11, 16-18, 24, 25}. In all these reports the removal of a conjunctival limbal donor graft, of different sizes, is described, but being as close as possible to its corneal insertion. In the present study this technique was utilized in Group 2 animals.

In most clinical series published on limbal transplantation, be it autologous or allogeneic, utilizing a live donor, no reports on complications regarding donor eyes are found, since these studies analyze primarily receptor eyes and do not emphasize follow-up of donors^{6, 23-25}.

Regarding reports describing complications in eyes with partial or total limbal deficiency, the following can be noted: granuloma-type lesion¹¹, epitheliopathy, corneal vascularization and "conjunctivalization"^{10, 26}.

Earlier studies by Huang and Tseng⁶ refer to corneal healing in rabbit eyes with total deficiency of the surgically removed corneal scleral limbus. In this experimental model, the corneas showed a healing delay, vascularization and recurrent erosions after two consecutive central epithelial defects.

Chen and Tseng¹⁴ in an experimental study with rabbits, removed two thirds of the corneal-conjunctival limbus and showed that the ocular surface may significantly decompensate after a great epithelial defect with irreversible signs of corneal "conjunctivalization". However, there was no destabilization of the ocular surface after two small consecutive epithelial defects. The same authors²⁷ also proved that partial limbal destruction may cause lighter forms of limbal deficiency and an abnormal corneal epithelization in the presence of a later great epithelial defect.

In our study a partial deficiency of one third of the limbus was provoked, in the attempt to simulate cases of limbal flap donors, with minimal limbal deficiency, since the above mentioned studies showed the alterations consequent to removal of a greater limbal circumference.

All the 40 eyes submitted to the two types of surgical procedure of removal of one third of the limbus (Groups 1 and 2) presented rapid epithelization. During a 21-day follow-up period there was no sign of destabilization of the ocular surface in the two groups, probably due to the fact that the remaining SC and TAC were sufficient to maintain cell renewal of the corneal epithelium. However we are not sure how many corneal insults these remaining cells can tolerate.

In order to study the residual proliferative ability of the eyes of our series, with partial corneal-conjunctival limbal (Group 1) and conjunctival limbal deficiency (Group 2), we applied two consecutive alkaline burns. We chose this type of corneal insult because it represents an important cause of ocular trauma to which donor eyes are exposed in daily life. We used two drops of a 0.5 N NaOH solution for 30 seconds,










**A última geração dos Alpha₂
comprovada na redução da PIC
comuns aos beta**



Alphagan

Tartarato de Brimonidina

**agonistas seletivos, com eficácia
em os efeitos cardiopulmonares
bloqueadores.**

-  **Eficácia comprovada no controle da PIO semelhante ao timolol.²**
-  **Maior seletividade (1.000 vezes mais seletivo) aos adrenoreceptores-alpha₂.⁴**
-  **Sem efeito clínico significativo na taxa cardíaca ou pressão sanguínea.²**
-  **Maior segurança para os pacientes com problemas cardiopulmonares.³**
-  **Duplo mecanismo de ação.¹**
-  **Não apresenta taquifilaxia.⁶**
-  **Praticidade posológica (2x ao dia).**



a lower concentration and less time than most experimental models of alkaline burn^{28, 29}. Our purpose was the complete removal of the corneal epithelium without causing large limbal ischemia. The same type of burn was applied to the normal eyes, which presented no sequelae.

In this study, eyes with partial limbal deficiency (a similar situation to limbus donor eyes) presented corneal healing time statistically similar to that of the control group. This difference probably would have been significant with a greater number of cases, since the removal of corneal conjunctival flap is more aggressive and probably causes a greater limbal deficiency.

When the area of the epithelial defect is taken into account (healing curve), we noted that eyes with limbal deficiency, after the two burns, have different from normal behavior, presenting greater defects with greater healing delay ($p < 0.05$). Analyzing Groups 1 and 2 in respect to the controls, we note that Group 1 (corneal-conjunctival graft) healed more slowly than the control with a significant difference at all studied times. Group 2 (conjunctival graft) behaved similarly to the control with the exception of day 3 of observation, after the two burns. The more aggressive surgical technique, utilized in Group 1 may be responsible for the results.

In addition to the eyes with limbal deficiency having significantly greater epithelial defects after the burns, these defects presented a delayed healing at the superior corneal third, adjacent to limbus removal. This fact is due to SC depletion of the excised limbus and the great TAC reduction at the corneal periphery thus leading to epithelial migration from the unharmed limbal periphery as has been shown previously³⁰.

Regarding corneal vascularization, there was no statistical difference between the groups. In the cases of vessel development, vascularization was always adjacent to the superior limbus, demonstrating that, even transiently, the superior limbal barrier was interrupted and that the epithelium with conjunctival characteristics advanced over the cornea¹⁹.

Corneal opacities are the direct consequence of the burn (extracellular glycosaminoglycan precipitation and alterations in collagen fibers) associated with stromal inflammation and persistence of the epithelial defects. After epithelial healing there occurs a decrease in inflammation and consequently in the cellular infiltrate³¹. Transient leukomas occurred much more in the eyes with partial limbal deficiency as compared with the controls. The difference was significantly greater in Group 1 after the first burn.

There was only one case (case 2 of Group 1) presenting vessels invading beyond 2 mm from the superior limbus, with leukoma and recurrent erosions which persisted until the end of follow-up (Fig. 1F). Sequelae such as vessels, recurrent epithelial defects and corneal opacity indicate corneal "conjunctivalization" and are directly proportional to SC impairment. This eye was submitted to the most invasive surgical procedure.

Impression cytology, used in cases of presence of goblet cells on the corneal surface, has been the method of choice to diagnose and monitor corneal diseases with limbal deficiency³². Since no material required for impression cytology was available, we opted for cytology using cytocentrifugation of a corneal epithelium sample removed by means of a nylon brush (Cytobrush®)²¹. This method was adequate for the detection of goblet cells in case 2 of Group 1. Absence of goblet cells, in the remaining cases evaluated, was not surprising, since at the time of examination only case 2 (Group 1) presented signs of conjunctival invasion in the superior corneal third (Fig. 1F).

Studies utilizing specific monoclonal antibodies for differentiated corneal epithelial cells (AE-5), characteristic of the corneal phenotype, and for mucin (AM-3), typical of the conjunctival phenotype, succeeded to prove that eyes with deficiency of two thirds of the limbus, submitted to two small epithelial defects developing vessels at the corneal periphery adjacent to limbus removal had a mixed conjunctival and corneal phenotype, at the corneal periphery, while the center remained normal¹⁴. Some of our cases in Groups 1 and 2 vascularized at the superior corneal periphery and perhaps analysis using monoclonal antibodies could show a mixed phenotype pattern, proving that there was localized "conjunctivalization" which could be the subject for further studies in this area.

In view of our results, we conclude that, if possible, considering that we are dealing with autologous and allogeneic transplantation utilizing related live donors, we should opt for a graft removal technique causing the least damage to the donor eye. We believe that conjunctival limbal graft removal, without keratectomy, is the best option in those cases where tissue from healthy eyes is removed from patients who are afraid of the procedure in their normal eye. Our results show that eyes with partial corneal conjunctival limbal deficiency, in the presence of corneal insults (burns), show a greater delay in corneal epithelization (healing curve) and greater chances of presenting complications than eyes with conjunctival limbal deficiency.

The good clinical results obtained in the series utilizing limbal transplantation^{11, 16-18, 24, 25} corroborate our impressions that the peripheral limbal conjunctiva carries a sufficient number of SC to supply the receptor eye. We believe that this technique of obtention of donor grafts is easier to be technically performed, not presenting all risks due too peripheral keratectomy, including perforation.

RESUMO

Objetivo: Comparar a cicatrização epitelial corneana de olhos de coelhos com deficiência parcial de limbo (DPL) córneo-conjuntival e conjuntival com olhos normais (controles).

Métodos: A DPL foi induzida pela retirada cirúrgica de 1/3 do limbo superior realizando uma ceratectomia a 2 mm do limbo (Grupo 1) e pela remoção do limbo conjuntival sem



A síndrome do olho seco
é uma questão de estabilidade
do filme lacrimal...

Chegou

Liquifilm + Povidona **dose única**® Refresh

Uma nova era no tratamento do olho seco,
que aumenta a estabilidade do filme lacrimal



**A única
lágrima artificial
sem preservativos
no Brasil**

◆ **MAIOR SEGURANÇA**

◆ **COMODIDADE POSOLÓGICA**

Flaconetes descartáveis
Dose única individual

◆ **TEMPO DE AÇÃO
MAIS PROLONGADO**

8 horas de ação eficaz
70% mais tempo de ação
que os outros polímeros

 **ALLERGAN**

Toll Free 0800-174077



ceratectomia (Grupo 2). Posteriormente, todos os olhos operados e os controles foram submetidos a duas queimaduras alcalinas consecutivas.

Resultados: Após a 1ª e 2ª queimaduras, os olhos do Grupo 1 tiveram uma curva de cicatrização epitelial significativamente mais lenta que os controles, os olhos do Grupo 2 e os controles tiveram curvas de cicatrização similares. As córneas dos Grupos 1 e 2 apresentaram mais vascularização periférica que os controles porém sem diferença significativa. A incidência de leucomas transitórios foi maior no Grupo 1 quando comparado aos controles ($p < 0.05$). Houve apenas um caso de leucoma permanente, vascularização e defeito epiteliais persistentes que pertencia ao Grupo 1. A avaliação citológica demonstrou células epiteliais normais, com exceção de um caso do Grupo 1 que apresentou células calciformes.

Conclusões: Nossos resultados sustentam o conceito de que nas córneas com DPL o epitélio ainda pode estar comprometido após uma queimadura moderada e que a remoção de limbo córneo-conjuntival causa uma DPL mais grave do que a remoção de limbo conjuntival. Além disso, trata-se de um procedimento tecnicamente mais difícil e invasivo para o olho doador.

REFERENCES

1. Thoft RA, Friend J. The X, Y, Z hypothesis of corneal epithelial maintenance. Invest Ophthalmol Vis Sci 1983;24:1442-3.
2. Hall PA, Watt FM. Stem cells: the generation and maintenance of cellular activity. Development 1989;106:619-33.
3. Schermer A, Galvin S, Sun TT. Differentiation-related expression of a major 64K corneal keratin in vivo and in culture suggests limbal location of corneal epithelial stem cells. J Cell Biol 1986;103:49-62.
4. Ebato B, Friend F, Thoft RA. Comparison of central and peripheral human corneal epithelium in tissue culture. Invest Ophthalmol Vis Sci 1987;28:1450-6.
5. Ebato B, Friend F, Thoft RA. Comparison of limbal and peripheral human corneal epithelium in tissue culture. Invest Ophthalmol Vis Sci 1988;29:1533-7.
6. Huang AJW, Tseng SCG. Corneal epithelial wound healing in the absence of limbal epithelial. ARVO Abstracts. Invest Ophthalmol Vis Sci 1988;29(Suppl):190.
7. Kenyon KR, Tseng SCG. Limbal autograft transplantation for ocular surface disorders. Ophthalmology 1989;96:709-23.
8. Durand L, Fages F, Burillon C. Greffe lamellaire cornéo-conjonctivale "inlay", premier temps préparatoire du traitement chirurgical des séquelles de brûlures de cornée. J Fr Ophthalmol 1990;13:17-23.
9. Ronk JF, Ruiz-Esmenjaud S, Osorio M et al. Limbal conjunctival autograft in a subacute alkaline corneal burn. Cornea 1994;13:465-8.
10. Tan DTH, Ficker LA, Buckley RJ. Limbal transplantation. Ophthalmology 1996;103:29-36.
11. Kwitko S, Marinho DR, Barcaro S, et al. Allograft conjunctival transplantation for bilateral ocular surface disorders. Ophthalmology 1995;102:1020-5.
12. Tsai RJF, Tseng SCG. Human Allograft Limbal Transplantation for corneal surface reconstruction. Cornea 1994;13:389-400.
13. Tsubota K, Toda I, Saito H et al. Reconstruction of the corneal epithelium by limbal allograft transplantation for severe ocular surface disorders. Ophthalmology 1995;102:1486-96.
14. Chen JJY, Tseng SCG. Corneal epithelial wound healing in partial limbal deficiency. Invest Ophthalmol Vis Sci 1990;31:1301-14.
15. Weise RA, Mannis MJ, Vastine DW et al. Conjunctival transplantation. Autologous and homologous grafts. Arch Ophthalmol 1985;103:1736-40.
16. Brill JRS. Cirurgia conjuntival por indicación corneal. Arch Chil Oftalmol 1991;48:73-80.
17. Clinch TE, Goins KM, Cobo LM. Treatment of contact lens-related ocular surface disorders with autologous conjunctival transplantation. Ophthalmology 1992;99:634-8.
18. Pfister RR. Corneal stem cell disease: Concepts, categorization and treatment by auto and homotransplantation of limbal stem cells. CLAO J 1994;20:64-72.
19. Thoft RA, Friend J, Murphy HS. Ocular surface epithelium and corneal vascularization in rabbits. The role of wounding. Invest Ophthalmol Vis Sci 1979;18:85-92.
20. Hughes WF. Alkali burns of the eye. Review of the literature and summary of present knowledge. Arch Ophthalmol 1946;35:423-49.
21. Tsubota K, Kajiura K, Ugajin S et al. Conjunctival brush cytology. Acta Cytol 1990;34:233-5.
22. Tsai RJF, Sun TT, Tseng SCG. Comparison of limbal and conjunctival autograft transplantation in corneal surface reconstruction in rabbits. Ophthalmology 1990;97:446-55.
23. Shimazaki J, Yang HY, Tsubota K. Limbal autograft transplantation for recurrent and advanced pterygia. Ophthalmic Surg Lasers 1996;27:917-23.
24. Cunha M, Allemann N. Transplante autólogo de conjuntiva no tratamento de pterígio primário e recidivado. Arq Bras Oftal 1993;56:78-91.
25. Carvalho MJ, Moura RC, Cunha M et al. Transplante autógeno de conjuntiva no tratamento de queimaduras graves. Arq Bras Oftal 1994;57:167-9.
26. Jenkins C, Tuft S, Liu C et al. Limbal transplantation in the management of chronic contact-lens associated epitheliopathy. Eye 1993;7:629-33.
27. Chen JJY, Tseng SCG. Abnormal corneal epithelial wound healing in partial-thickness removal of limbal epithelium. Invest Ophthalmol Vis Sci 1991;32:2219-33.
28. Chung JH. Healing of rabbit corneal alkali wounds in vitro. Cornea 1990;9:36-40.
29. Saika S, Uenoyama K, Hiroi K et al. Ascorbic acid phosphate ester and wound healing in rabbit corneal alkali burns: epithelial basement membrane and stroma. Graefes Arch Clin Exp Ophthalmol 1993;231:221-7.
30. Dua HS, Gomes JAP, Singh A. Corneal epithelial wound healing. Br J Ophthalmol 1994;78:401-8.
31. Wagoner MD. Chemical injuries of the eye: current concepts in pathophysiology and therapy. Surv Ophthalmol 1997;41:275-313.
32. Puangsricharem V, Tseng SC. Cytologic evidence of corneal diseases with limbal stem cell deficiency. Ophthalmology 1995;102:1476-85.

Novidades na Internet!!!

Agora no site CBO você tem disponível todas as informações na íntegra dos

Arquivos Brasileiros de Oftalmologia

<http://www.cbo.com.br/abo>

Depois de 3 minutos... VISCOAT® ainda cobre 90 por cento das células endoteliais da córnea.



HEALON* 7%
(coesivo)

AMVISC PLUS* 17%
(coesivo)

VISCOAT® 90%
(dispersivo)

A proteção endotelial depende de um viscoelástico que ofereça uma barreira física. Não somente no início do procedimento, mas uma barreira prolongada. *A solução viscoelástica VISCOAT mostrou ter um grande poder de permanência, que irá ajudá-lo a obter "uma faco bem sucedida".*

Após 3 minutos de irrigação e aspiração com a ponteira de faco, um novo estudo demonstrou que 90% das delicadas células endoteliais ainda tinham uma camada dispersiva de VISCOAT, cobrindo-as e protegendo-as de toques físicos inadvertidos.¹ Os outros viscoelásticos, que são coesivos em comportamento, saem mais facilmente do olho, reduzindo a proteção endotelial durante o procedimento típico de facoemulsificação.



Veja a diferença que o poder de permanência de VISCOAT fará nos seus procedimentos de faco.

VISCOAT® - solução viscoelástica - a proteção permanece mesmo depois que as outras soluções desaparecerem.

"A Solução Facoelástica"

¹ Arshinoff, S., Poyer, J.F., An in vitro Method to Assess the Resistance of Removal of a Viscoelastic Layer from a Corneal Endothelial Cell Surface by Irrigation and Aspiration. Presented at the 1996 ASCRS.

* Healon is a registered trademark of Pharmacia Inc.;
Amvisc Plus is a registered trademark of Chiron Vision Corp.
Alcon® and Viscoat® are registered trademarks for Alcon Laboratories, Inc.

Alcon
BRASIL