

Intraocular lens opacification

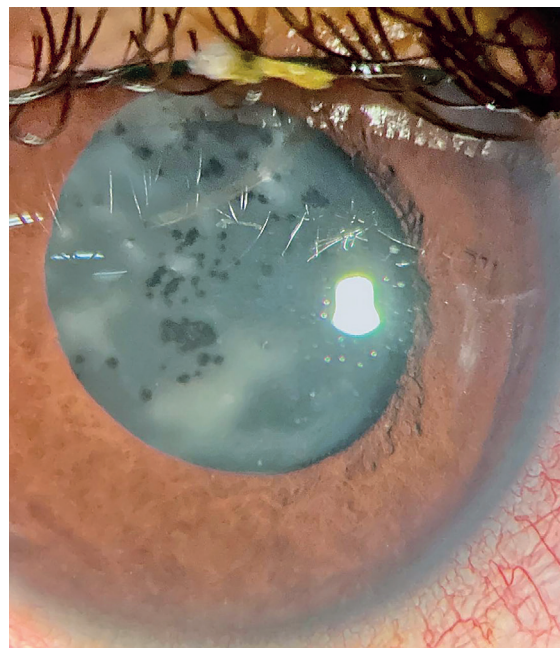
Pedro Henrique Oliveira Ribeiro¹ , Nicole Bulgarão Maricondi de Almeida¹ , Newton Kara-Júnior¹ 

1. Ophthalmology department, Hospital das Clínicas, Universidade de São Paulo, São Paulo, SP, Brazil.

Although intraocular lens opacification is uncommon, multiple different patterns of opacities have been described according to the intraocular lens material. A well-known complication of silicone lenses is the adherence of silicone droplets on the lens surface after silicone oil injection at the time of retinal surgery. These droplets are nearly impossible to displace (Figure 1). Furthermore, these droplets hamper the patient's vision as well as the physician's view of the posterior pole. Thus, the compromised intraocular lens will require an exchange⁽¹⁾.

REFERENCES

1. Durr GM, Ahmed IIK. Intraocular lens complications: decentration, uveitis-glaucoma-hyphema syndrome, opacification, and refractive surprises. *Ophthalmology*. 2021;128(11):e186-e194.



Submitted for publication: December 16, 2024

Accepted for publication: December 17, 2024

Funding: This study received no specific financial support.

Disclosure of potential conflicts of interest: The authors declare no potential conflicts of interest.

Corresponding author: Nicole Bulgarão M. Almeida.

E-mail: nickbma204@gmail.com

Informed consent was obtained from all patients included in this study.

 This content is licensed under a Creative Commons Attributions 4.0 International License.